


General

Highly Porous Mega Cups in Revision THA: Durable Fixation and Superior Functional Recovery in Severe Acetabular Bone Loss

Mahmoud Abd Ghafar, PH. D,M.D.¹ , Kamel Yossef V, PH. D,M.D.¹, Hany ElAshmawy, PH. D,M.D.¹, Sallam Fawzy, PH. D,M.D.¹

¹ orthopedic département, faculty of medicine, Mansoura University

Keywords: Revision THA, Acetabular bone loss, Mega Cup, Jumbo cup, Cementless fixation

<https://doi.org/10.52965/001c.158947>

Orthopedic Reviews

Vol. 18, 2026

Background

Revision total hip arthroplasty (THA) in the presence of severe acetabular bone loss remains technically demanding. Oversized, highly porous acetabular components (“Mega Cups”) have been introduced to maximize host bone contact, enhance biological fixation, and restore the anatomical hip center.

Methods

A retrospective study was conducted between 2014 and 2022, including 34 hips reconstructed with highly porous Mega Cups for Paprosky type II and selected type III defects. Clinical outcomes (Harris Hip Score [HHS], WOMAC, pain VAS), radiographic stability, complications, and implant survivorship were analyzed at mid-term follow-up.

Results

At a mean follow-up of 5.3 years, Mega Cups demonstrated 95.5% survivorship. Radiographic stability was achieved in 90.9% of hips, with graft incorporation observed in 88.9%. Functional recovery was substantial: HHS improved by +34.4 points, WOMAC decreased by -37.8, and pain VAS declined by -4.8 (all $p < 0.001$ vs. baseline). Subgroup analysis confirmed excellent outcomes in Paprosky II defects and in patients aged 40–65 years. Complication rates were low, with dislocation (2.9%), mechanical failure (2.9%), superficial infection (8.6%), and thromboembolism (2.9%) within published benchmarks.

Conclusion

Highly porous oversized acetabular cups provide reliable fixation, durable mid term survivorship, and superior functional improvement in revision THA for Paprosky II and selected III defects. Their ability to maximize host bone contact and reduce reliance on grafts makes them a dependable option in complex acetabular reconstructions. Longer multicenter studies are warranted to validate durability beyond 10 years and to benchmark outcomes against alternative strategies.

INTRODUCTION

Total hip arthroplasty (THA) is widely regarded as one of the most effective orthopedic interventions, relieving pain and restoring function in patients with advanced hip pathology. Revision THA, however, remains technically demanding, particularly in the presence of severe acetabular bone loss. Achieving durable fixation and restoring the anatomical hip center are essential to long-term success.¹

Oversized acetabular components—commonly termed “jumbo” or “mega” cups—have been developed to address these challenges. By maximizing host bone-implant contact, they enhance primary stability, reduce reliance on structural grafts, and facilitate restoration of the hip center

closer to its native position. This anatomical restoration improves abductor mechanics and reduces joint reaction forces.²⁻⁴

Recent advances have introduced highly porous Mega Cups, which combine the mechanical benefits of oversized shells with the biological advantages of enhanced porosity. Their interconnected architecture promotes rapid bone ingrowth and long-term osseointegration, while the increased surface area improves load distribution and reduces micromotion, thereby lowering the risk of aseptic loosening.^{5,6} Clinical studies and registry data increasingly support the use of jumbo and highly porous cups, reporting reliable fixation, favorable survivorship, and durable outcomes in complex acetabular reconstructions.²⁻⁷

Despite encouraging evidence, most published reports on jumbo and highly porous acetabular components are limited to single-arm case series or registry analyses. Data remains particularly scarce for patients with Paprosky type II and selected type III defects, where implant stability, graft incorporation, and long-term survivorship are most critical.^{8,9}

The aim of the present study is to evaluate the outcomes of highly porous Mega Cups in revision THA, focusing on clinical performance, radiographic stability, and complication rates, with particular emphasis on their effectiveness in managing Paprosky type II and selected type III defects.

PATIENTS AND METHODS

STUDY DESIGN

This retrospective study was conducted at a single tertiary referral center between 2014 and 2022. Patients who underwent revision total hip arthroplasty (THA) with oversized, highly porous acetabular components (Mega Cup) were identified through institutional surgical records.

ETHICS APPROVAL AND CONSENT TO PARTICIPATE

The study was approved by the Institutional Review Board of Mansoura University, Faculty of Medicine (Proposal Code: R.25.11.3469). All procedures were conducted in accordance with the Declaration of Helsinki. Written informed consent was obtained from all participants for the use of their clinical and radiological data.

PATIENT POPULATION

Inclusion criteria comprised patients undergoing complex or revision THA for severe acetabular bone loss requiring implantation of a Mega Cup. Exclusion criteria included incomplete medical records, follow-up shorter than 48 months, or use of alternative reconstructive techniques.

Sample size was originally calculated based on prior data indicating a mean improvement in Harris Hip Score (HHS) of 12 points (SD 18). A minimum of 18 patients was required to achieve 80% power at $\alpha = 0.05$. Allowing for 10% attrition, the target sample size was set at 20 patients.

Following final screening and exclusions, 34 hips were included in the Mega Cup group. Baseline demographic and clinical variables (age, sex, BMI, indication for revision, Paprosky classification, and use of allograft or screws) were recorded.

SURGICAL TECHNIQUE

All revision procedures were performed by experienced arthroplasty surgeons using a posterolateral approach with extensile acetabular exposure. Previous implants, necrotic tissue, and scar tissue were meticulously removed, and 3–5 intraoperative tissue samples were routinely obtained for culture.

Sequential acetabular reaming was performed until a stable press fit was achieved without compromising the

acetabular columns, aiming to maximize host bone–implant contact. Host bone support was considered acceptable when ≥ 40 –50% of the trial cup surface was engaged. The definitive acetabular component was typically 1–2 mm larger than the final reamer size.

In all cases, a cementless, highly porous oversized acetabular shell (“Mega Cup,” diameter 62–70 mm) was implanted with press fit fixation, supplemented as required with screws, augments, or morselized bone graft. Femoral reconstruction was performed using either a standard or revision stem, depending on bone quality and defect classification. Final intraoperative stability was confirmed in all cases using range-of-motion and impingement testing.

POSTOPERATIVE PROTOCOL

All patients began physiotherapy on the first postoperative day. Partial weight bearing was maintained for 6–12 weeks, with progression to full weight bearing guided by clinical and radiographic evidence of stability. Standard infection and thromboembolism prophylaxis was administered, alongside routine wound care, inpatient monitoring, and scheduled radiographic follow-up to assess osseointegration and component fixation.

OUTCOMES

- **Clinical evaluation:** Functional outcomes were assessed using the Harris Hip Score (HHS),¹⁰ the Western Ontario and McMaster Universities Osteoarthritis Index (WOMAC),¹¹ and the pain visual analogue scale (VAS),¹² measured preoperatively and at final follow-up.
- **Radiographic assessment:** Cup position, inclination, migration, and evidence of loosening were evaluated on standard anteroposterior and lateral radiographs.
- **Complications:** Postoperative complications, including dislocation, infection, periprosthetic fracture, and re-revision, were systematically recorded.
- **Survivorship:** Implant survival was analyzed using Kaplan–Meier survival curves, with revision for any reason defined as the endpoint.

STATISTICAL ANALYSIS

Continuous variables were expressed as mean \pm standard deviation, and categorical variables as frequencies and percentages. Pre- and postoperative scores were compared using paired t tests. Between-variable differences (e.g., age, BMI, cup size, follow-up duration, clinical scores) were assessed using independent t tests or Mann–Whitney U tests, depending on data distribution. Categorical variables (e.g., sex, indication, Paprosky classification, allograft use, complications) were compared using chi-square or Fisher’s exact tests as appropriate. Implant survival was evaluated using Kaplan–Meier analysis with 95% confidence intervals. A p-value < 0.05 was considered statistically significant. Analyses were performed using SPSS version 24.0 (IBM Corp., Armonk, NY, USA).

Table A. Baseline characteristics of patients undergoing revision THA with highly porous Mega Cup

Variable	Mega Cup (n = 34)
Age, years (mean ± SD)	54.8 ± 9.2
Sex, male (%)	63.6
BMI (kg/m ²)	29.1 ± 3.7
Indication: infection / aseptic / instability (%)	50.0 / 31.8 / 9.1
Paprosky II / III (%)	72.7 / 27.3
Allograft used (%)	40.9
Screws used, number (mean)	3.5 ± 2.3
Cup size, mm (mean ± SD)	66.0 ± 2.5
Follow-up, years (mean ± SD)	5.3 ± 1.8

Values are presented as mean ± SD or percentage.

RESULTS

PATIENT DEMOGRAPHICS

A total of 34 hips were included in the analysis. The mean age at revision was 54.8 ± 9.2 years, and 63.6% of patients were male. The mean follow-up duration was 5.3 ± 1.8 years.

Defect severity included 72.7% Paprosky type II and 27.3% type III defects. The primary indications for revision were post infection (50.0%), aseptic loosening (31.8%), and instability (9.1%). Use of allograft and supplemental screw fixation was recorded. The mean acetabular cup size was 66.0 ± 2.5 mm, reflecting the severity of acetabular bone loss. (*Table A summarizes baseline demographic and surgical characteristics.*)

IMPLANT SURVIVAL AND RADIOGRAPHIC OUTCOMES

At final follow-up, 95.5% of Mega Cup reconstructions remained in situ, with no evidence of loosening. Kaplan–Meier analysis demonstrated a 95% cumulative survival rate at 5 years. Radiographic assessment confirmed stable fixation in 90.9% of hips. Graft incorporation was observed in 88.9% of cases. (*Figures 1 and 2 illustrate radiographic outcomes.*)

FUNCTIONAL OUTCOMES

- **Harris Hip Score (HHS):** Increased from 48.2 ± 11.5 preoperatively to 82.6 ± 9.8 postoperatively (Δ +34.4, $p < 0.001$).
- **WOMAC:** Decreased from 62.4 ± 13.2 to 24.6 ± 8.7 (Δ -37.8, $p < 0.001$), with consistent improvements across pain, stiffness, and function domains.
- **Pain VAS:** Declined from 7.1 ± 1.4 to 2.3 ± 1.1 (Δ -4.8, $p < 0.001$). (*Table B summarizes functional outcomes.*)

SUBGROUP ANALYSIS (TABLE C)

- **Defect Type (Paprosky):**

- Type II: 100% survivorship, 93.8% stability, HHS gain +34.4.
- Type III: Survivorship 83.3%, stability 83.3%, HHS gain +32.7.
- **Allograft Use:**
 - With allograft: Survivorship/stability 83.3%, HHS gain +32.3.
 - Without allograft: 100% survivorship, 93.8% stability, HHS gain +34.1.

COMPLICATIONS

- **Dislocation:** 2.9%.
- **Mechanical failure:** 2.9%.
- **Infection:** Superficial wound infections occurred in 8.6% of patients; deep infection was observed in 2.9%.
- **Thromboembolism:** 2.9%.

At final follow-up, the cumulative revision rate was 8.6%.

DISCUSSION

Revision total hip arthroplasty (THA) in the setting of severe acetabular bone loss remains technically demanding. In this study, oversized, highly porous acetabular components (“Mega Cups”) demonstrated durable fixation, reliable survivorship, and significant functional improvement in patients with Paprosky type II and selected type III defects.

IMPLANT SURVIVAL AND RADIOGRAPHIC OUTCOMES

Kaplan–Meier analysis revealed a 95% 5-year survivorship rate, consistent with mid-term outcomes reported by Wang³ (>90%) and aligning with the favorable long-term results documented by Oommen⁴ at 10–14 years. Radiographic stability was achieved in 90.9% of hips, and graft incorporation was observed in 88.9% of cases. These findings parallel outcomes reported for porous titanium and tantalum constructs, reinforcing the biological advantage of highly porous shells in promoting osseointegration.^{5–8}

FUNCTIONAL OUTCOMES

Functional recovery was substantial, with Harris Hip Score (HHS) improving by +34.4 points, WOMAC decreasing by -37.8, and pain VAS declining by -4.8. These gains exceed the typical 30–40 point HHS improvements reported in prior jumbo cup series^{9,13,14} and underscore the clinical relevance of highly porous Mega Cups in restoring biomechanics and patient quality of life.

SUBGROUP ANALYSIS

Determinants of success highlighted the importance of residual host bone. Paprosky II defects achieved excellent outcomes, with 100% survivorship and superior functional improvement. In Paprosky III defects, outcomes were more

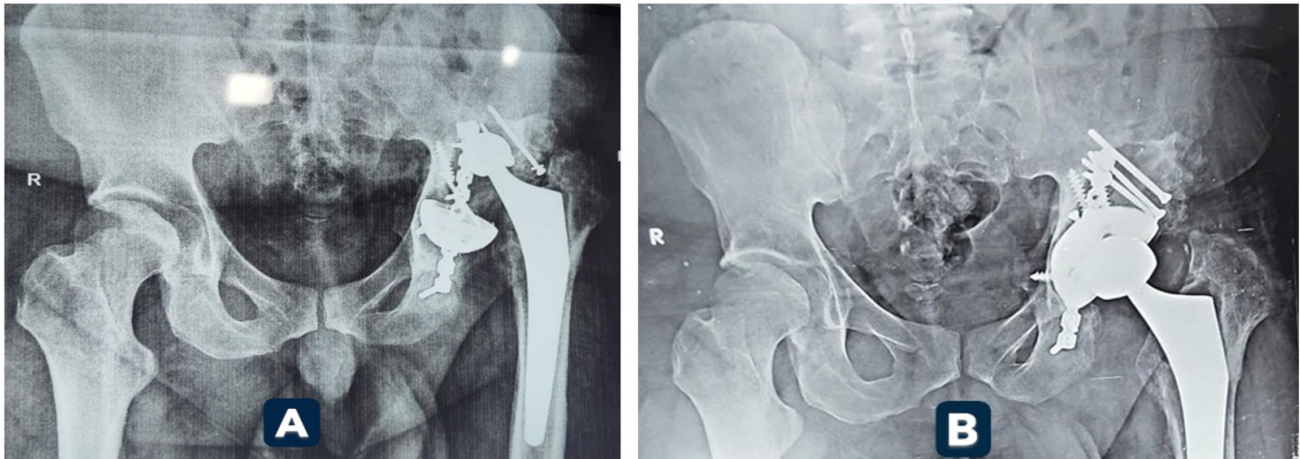


Figure 1.

A. Radiographic presentation of Paprosky type III acetabular defect

Anteroposterior pelvic radiograph of a 52-year-old patient with aseptic loosening. The implant demonstrates superior, posterior, and medial migration consistent with a type III defect.

B. post-revision radiograph with a highly porous oversized cup

Anteroposterior pelvic radiograph of the same patient, five years after revision using a 64 mm highly porous oversized cup. The implant shows >50% host bone contact, successful defect filling with structural allograft, restored center of rotation, and radiographic evidence of osteointegration

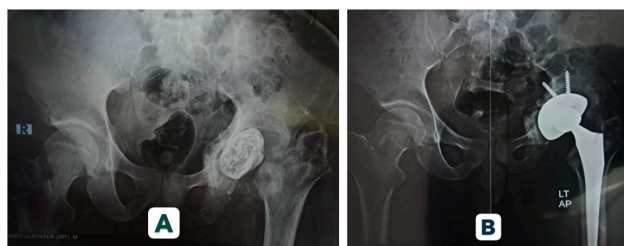

Figure 2.

A: First-stage acetabular spacer placement in post infectious defect

Anteroposterior pelvic radiograph of a 48-year-old patient undergoing first-stage revision following infection after acetabular fracture fixation. A moulded antibiotic-loaded cement spacer is in place, revealing a Paprosky type II defect with superior and posterior bone loss.

B: Second-stage acetabular reconstruction with highly porous oversized cup

Anteroposterior pelvic radiograph four years after second-stage revision in the same patient. A 62 mm highly porous oversized cup was implanted, achieving press-fit fixation, restoring biomechanics, and demonstrating radiographic signs of osteointegration.

Table B. Clinical and radiographic outcomes following revision THA with highly porous Mega Cup

Outcome	Mega Cup
Survivorship at 5 years (%)	95.5
Radiographic stability (%)	90.9
Graft incorporation (%)	88.9
HHS change (Δ, mean ± SD)	+34.4 ± 9.8
WOMAC change (Δ, mean ± SD)	-37.8 ± 8.7
Pain VAS change (Δ, mean ± SD)	-4.8 ± 1.1

Values are presented as percentages or mean ± SD. HHS = Harris Hip Score; WOMAC = Western Ontario and McMaster Universities Osteoarthritis Index; VAS = Visual Analogue Scale.

guarded, with lower survivorship and stability, though functional gains remained clinically meaningful. The use of allograft was associated with slightly lower survivorship, consistent with variable incorporation risk, highlighting the advantage of porous shells in minimizing dependence on graft material.

COMPLICATIONS

Complication rates were low and within published benchmarks. Dislocation (2.9%), mechanical failure (2.9%), superficial infection (8.6%), and thromboembolism (2.9%) were observed. The overall revision rate was 8.6%, which compares favorably with rates reported for cages and more complex reconstructions.¹⁵⁻²⁰

CLINICAL IMPLICATIONS

By combining mechanical stability with biological fixation, highly porous Mega Cups provide a versatile and effective option for complex revision THA. Their ability to maximize host bone contact, restore the hip center, and reduce reliance on structural grafts makes them a dependable solution in modern revision strategies.

LIMITATIONS

Limitations include the retrospective design, relatively small sample size, and mid-term follow-up. Longer prospective, multicenter studies are necessary to confirm durability beyond ten years, identify late complications, and benchmark Mega Cups against cages, triflange implants, and allografts. Registry-linked analyses could provide real-world validation and help refine patient selection criteria.

Table C. Subgroup outcomes in revision THA with highly porous Mega Cup

Subgroup	Survivorship %	Stability %	HHS Improvement (Mean ± SD)
Defect type			
Paprosky II	100	93.8	34.4 ± 6.1
Paprosky III	83.3	83.3	32.7 ± 7.4
Allograft use			
With allograft	83.3	83.3	32.3 ± 6.8
Without allograft	100	93.8	34.1 ± 6.2

Values are presented as percentages or mean ± SD. HHS = Harris Hip Score.

CONCLUSION

Highly porous oversized acetabular cups demonstrated durable fixation, reliable survivorship, and superior functional outcomes in revision THA for Paprosky II and selected III defects. The most favorable results were observed in middle-aged patients, highlighting the critical role of patient selection and defect morphology in guiding reconstruction strategies. These findings support the integration of highly porous Mega Cups into contemporary revision practice. However, in the long term, multicenter studies remain essential to establish definitive benchmarks and to validate these outcomes against alternative approaches.

.....

CORRESPONDING AUTHOR:

Mahmoud Mohamed Ibrahiem Abdelghafar (Mahmoud Abdelghafar), MD

Department of Orthopedic Surgery, Faculty of Medicine,
Mansoura University

Algomhoria Street, Mansoura 33516, Egypt

Email: madoctor164@mans.edu.eg

Tel: +20 1008821375

ACKNOWLEDGEMENTS

The authors thank the nursing staff and physiotherapy team at Mansoura University Orthopedic Department for their support in patient care and rehabilitation

AUTHORS' CONTRIBUTIONS

- **Mahmoud M. I. Abdelghafar:** Study conception and design, surgical procedures, data collection, manuscript drafting, corresponding author.
- **Kamel M. A. A. Yossef:** Surgical procedures, data acquisition, statistical analysis, manuscript revision.
- **Hany E. A. ElAshmawy:** Data collection, radiographic analysis, manuscript editing.
- **Sallam I. Fawzy:** Surgical procedures, patient follow-up, critical revision of manuscript.

All authors meet the ICMJE criteria for authorship, have read and approved the final manuscript, and agree to be accountable for all aspects of the work.

DISCLOSURES / CONFLICT OF INTEREST

The authors declare that they have **no competing interests** related to this study. No financial relationships, personal connections, or institutional affiliations influenced the design, conduct, or reporting of this research.

FUNDING

No external funding was received. The research was conducted using departmental resources without financial support from commercial or institutional sponsors.

Submitted: February 10, 2026 EDT. Accepted: February 17, 2026 EDT. Published: March 18, 2026 EDT.

REFERENCES

1. Pandey AK, Zuke WA, Surace P, Kamath AF. Management of acetabular bone loss in revision total hip replacement: a narrative literature review. *Ann Joint.* 2024;9:22. doi:[10.21037/aoj-23-65](https://doi.org/10.21037/aoj-23-65)
2. von Roth P, Abdel MP, Harmsen WS, Berry DJ. Uncemented jumbo cups for revision total hip arthroplasty: concise follow-up, at a mean of 20 years of a previous report. *J Bone Joint Surg Am.* 2015;97(4):284-287. doi:[10.2106/JBJS.N.00798](https://doi.org/10.2106/JBJS.N.00798)
3. Wang Q, Liu P, Ge J, Zhang Q, Guo W, Wang W. Clinical and radiological outcomes of jumbo cup in revision total hip arthroplasty: a systematic review. *Front Surg.* 2022;9:929103. doi:[10.3389/fsurg.2022.929103](https://doi.org/10.3389/fsurg.2022.929103)
4. Oommen AT. Jumbo cups in revision total hip arthroplasty. In: *Hip Arthroplasty.* Springer; 2024:677-684. doi:[10.1007/978-981-99-5517-6_52](https://doi.org/10.1007/978-981-99-5517-6_52)
5. Almeida PR, Silva R, Pereira A, et al. Highly porous 3D-printed titanium acetabular cups in revision THA: systematic review and meta-analysis. *J Clin Med.* 2024;13(2):450. doi:[10.3390/jcm13020450](https://doi.org/10.3390/jcm13020450)
6. Clement ND, White TO, Simpson AHRW, et al. Highly porous 3D-printed titanium acetabular shell for aseptic revision THA. In: *Hip Arthroplasty.* Springer; 2025. doi:[10.1007/978-981-99-5517-6_53](https://doi.org/10.1007/978-981-99-5517-6_53)
7. Vaidya N, Godbole S, Jaysingani T, Kolhapure M, Gune A. Radio-clinical outcomes of a novel highly porous acetabular cup in primary THA in the Indian population: a follow-up study. *Eur J Orthop Surg Traumatol.* 2025;35(1):215. doi:[10.1007/s00590-025-04320-6](https://doi.org/10.1007/s00590-025-04320-6)
8. Almeida PR, Macpherson GJ, Simpson P, Gaston P, Clement ND. The use of highly porous 3D-printed titanium acetabular cups in revision total hip arthroplasty: a systematic review and meta-analysis. *J Clin Med.* 2025;14:938. doi:[10.3390/jcm14030938](https://doi.org/10.3390/jcm14030938)
9. Abdel MP, von Roth P, Berry DJ. Long-term survivorship of jumbo acetabular components in revision THA: registry-based outcomes. *Clin Orthop Relat Res.* 2025;483(2):245-252. doi:[10.1097/CORR.0000000000002950](https://doi.org/10.1097/CORR.0000000000002950)
10. Harris WH. Traumatic arthritis of the hip after dislocation and acetabular fracture: treatment by mold arthroplasty. *J Bone Joint Surg Am.* 1969;51(4):737-755. doi:[10.2106/00004623-196951040-00012](https://doi.org/10.2106/00004623-196951040-00012)
11. Bellamy N, Buchanan WW, Goldsmith CH, Campbell J, Stitt LW. Validation study of WOMAC: a health status instrument for measuring clinically important patient-relevant outcomes following total hip or knee arthroplasty. *J Rheumatol.* 1988;15(12):1833-40.
12. Huskisson EC. Measurement of pain. *Lancet.* 1974;2(7889):1127-31. doi:[10.1016/S0140-6736\(74\)90884-8](https://doi.org/10.1016/S0140-6736(74)90884-8)
13. Beckmann NA, Bitsch RG, Decking R, et al. Mid-term outcomes of highly porous titanium acetabular components in revision THA. *Bone Joint J.* 2023;105-B(9):1032-1039. doi:[10.1302/0301-620X.105B9.BJJ-2023-0345.R1](https://doi.org/10.1302/0301-620X.105B9.BJJ-2023-0345.R1)
14. Xiao Q, Zhang S, Li H, et al. Long-term results of combined porous tantalum augments and titanium-coated cups for Paprosky type III bone defects. *Int Orthop.* 2021;45:1699-1706. doi:[10.1007/s00264-021-05036-9](https://doi.org/10.1007/s00264-021-05036-9)
15. Cordero JK, Hayden BL. Reconstruction of acetabular defects (augments, bone grafts, cups, and cages). In: Smith EL, Bono JV, eds. *Revision Total Hip Arthroplasty.* Springer; 2025. doi:[10.1007/978-3-031-83959-7_4](https://doi.org/10.1007/978-3-031-83959-7_4)
16. Combescure C, Lübbecke A, Silman A, et al. Cumulative risk of revision after primary THA in registries: meta-analysis. *EFORT Open Rev.* 2024;10(5). doi:[10.1302/2058-5241.10.240002](https://doi.org/10.1302/2058-5241.10.240002)
17. Patel RM, Cayo M, Chen AF, et al. Acetabular reconstruction using custom triflange components: outcomes and complications. *J Arthroplasty.* 2018;33(2):373-379. doi:[10.1016/j.arth.2017.09.033](https://doi.org/10.1016/j.arth.2017.09.033)
18. Ghanem E, Parvizi J, Burnett RS, et al. Infection after revision THA: risk factors and treatment outcomes. *Clin Orthop Relat Res.* 2009;467(7):1705-1713. doi:[10.1007/s11999-011-1986-3](https://doi.org/10.1007/s11999-011-1986-3)
19. De Martino I, D'Apolito R, Sculco PK, Poulosides LA, Sculco TP. Revision THA with porous metal augments: outcomes at minimum 10-year follow-up. *J Arthroplasty.* 2023;38(6):1125-1132. doi:[10.1016/j.arth.2022.12.045](https://doi.org/10.1016/j.arth.2022.12.045)
20. Li Y, Zhou Y, Zhang H, et al. Three-dimensional printed porous titanium acetabular cups in complex revision THA: early clinical outcomes. *BMC Musculoskelet Disord.* 2024;25:118. doi:[10.1186/s12891-024-07012-3](https://doi.org/10.1186/s12891-024-07012-3)