Cawley D, Richard L, Brophy W, Rodriguez Anaya L. Heel cord advancement for spastic equinus in pediatric cerebral palsy: historical perspectives and contemporary appraisal. *Orthopedic Reviews*. 2026;18. doi:10.52965/001c.173778

General

Heel cord advancement for spastic equinus in pediatric cerebral palsy: historical perspectives and contemporary appraisal

Daniel Cawley, DC, MS, MSHS[1][a], Leighton Richard, BS[1], William Brophy, DO[2], Luis Rodriguez Anaya, DPM[3]

[1] Biomedical Sciences - Auburn campus, Edward Via College of Osteopathic Medicine, [2] Orthopedic Surgery, HCA Florida Ocala Hospital, [3] School of Podiatric Medicine, Barry University

Keywords: cerebral palsy, equinus deformity, heel cord advancement, Achilles tendon surgery, pediatric orthopedics

https://doi.org/10.52965/001c.173778

Orthopedic Reviews

Vol. 18, 2026

Spastic equinus is the most common lower-extremity deformity in children with cerebral palsy and can impair gait and mobility. Heel cord advancement detaches and advances the Achilles tendon insertion anteriorly on the calcaneus to reduce the plantarflexion lever arm and improve ankle position during gait. Although biomechanical models suggest that the procedure may reduce plantarflexion leverage while preserving some push-off, clinical evidence remains limited.

This narrative review used targeted searches of major medical databases to identify studies of heel cord advancement in pediatric cerebral palsy. Studies reporting surgical technique, postoperative management, functional or gait outcomes, or complications were included. Nine studies involving 359 patients were identified, with follow-up ranging from 1 to 9.7 years. Most were retrospective case series or cohort studies. Reporting of gross motor function, instrumented gait analysis, recurrence, overcorrection, and crouch-related outcomes was inconsistent.

Heel cord advancement was associated with improved gait classification, ankle dorsiflexion, and selected functional measures in some cohorts. Interpretation was limited by heterogeneous populations, inconsistent outcome definitions, frequent concomitant procedures, and inadequate control for maturation or baseline function. Recurrent equinus was the most frequently reported complication; while overcorrection, calcaneal gait, and postoperative crouch were insufficiently assessed.

Heel cord advancement may benefit selected children, but evidence does not establish superiority over other procedures, permanence of equinus correction, or preservation of push-off strength. Prospective comparative studies with standardized functional classification, gait analysis, validated outcomes, and long-term follow-up are needed.

1. INTRODUCTION

Equinus foot represents the most prevalent deformity in children with cerebral palsy (CP).[1] In this population, equinus deformity may arise from dynamic spasticity, fixed contracture, or a combination of both within the gastrocnemius–soleus complex, resulting in excessive plantarflexion and restricted ankle dorsiflexion.[2] This condition disrupts normal gait mechanics by limiting heel strike at initial contact and may lead to forefoot or midfoot landing, early heel rise, or compensatory gait patterns such as hip hiking, circumduction, or contralateral vaulting to facilitate toe clearance.[3,4] These compensatory mechanisms can increase energy expenditure and impose additional stress on the joints of the lower extremity and spine.[5,6] Without intervention, clinically significant equinus may impair ambulation, reduce gait efficiency, and elevate fall risk, resulting in broader functional consequences.[7,8]

Management of spastic equinus encompasses both nonoperative and operative strategies aimed at improving ankle alignment, gait mechanics, functional mobility, and brace tolerance. Initial interventions typically include physical therapy, ankle-foot orthoses (AFOs), and botulinum toxin injections to mitigate dynamic spasticity and optimize rehabilitation outcomes.[9-12] Surgical intervention is indicated when nonoperative measures are unsuccessful or when fixed contracture significantly contributes to the deformity. Common surgical procedures include gastrocne-

a **Corresponding author:** Daniel R. Cawley, Department of Biomedical Affairs and Research, Edward Via College of Osteopathic Medicine, 910 South Donahue Drive, Auburn, AL, 36832, USA. Telephone: +1(334)442-4105. Email: dcawley@vcom.edu

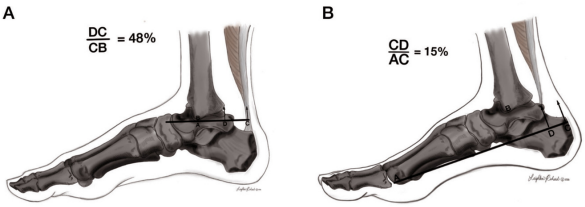

Figure 1. Theoretical basis for heel cord advancement. (a) Transferring the Achilles tendon from point C to point D reduces gastrocnemius–soleus lever-arm by 48% while (b) reducing push-off lever-arm by only 15%.

mius recession, gastrocsoleus recession, and tendo-Achilles lengthening (TAL).[13,14]

Surgical correction of equinus in CP requires balancing the correction of plantarflexion deformity with the risk of excessive plantarflexor weakening. The gastrocnemius–soleus complex plays a key role in controlling tibial advancement during stance and contributing to knee extension through the plantar flexion–knee extension couple.[15] Excessive weakening or lengthening of the plantarflexor muscle/tendon may result in calcaneal gait, diminished push-off, increased knee flexion during stance, or progressive crouch, particularly in children with bilateral involvement.[13,15] Surgical decision-making should therefore consider the distribution of cerebral palsy involvement, baseline ambulatory and functional status, physical examination findings, and, when available, standardized functional assessment and instrumented gait analysis.

Heel cord advancement (HCA), initially described by Esteve and subsequently popularized by Pierrot and Murphy, entails detachment of the Achilles tendon insertion from the calcaneus and anterior advancement of the tendon insertion to decrease the plantarflexion moment arm.[16,17] Early geometric models suggested that anterior advancement could provide adequate correction of equinus by reducing gastrocnemius plantarflexion leverage by 48% (Figure 1a) while only reducing late-stance push-off by 15% (Figure 1b).[17-19] The theoretical distinction between HCA and other surgical techniques has been identified as a potential biomechanical advantage. However, preservation of push-off has not been demonstrated using contemporary instrumented gait analysis, ankle kinetics, or plantarflexor power measurements. Additionally, simplified lever-arm models may inadequately represent gait mechanics in children with cerebral palsy, as impaired motor control, muscle weakness, altered muscle properties, and lever-arm dysfunction can affect the plantarflexion–knee extension couple.[20,21]

Although HCA has been described for over five decades, it remains an uncommon and relatively understudied procedure for equinus correction in cerebral palsy. Existing literature primarily comprises retrospective case series involving heterogeneous patient populations, variable use of adjunctive procedures, inconsistent reporting of functional outcomes, and limited objective preoperative and postoperative data. This narrative review aims to critically summarize the published literature on HCA in pediatric cerebral palsy, focusing on surgical technique, postoperative management, clinical and functional outcomes, complications, comparative evidence, and limitations of the current evidence base.

METHODS

A narrative review was conducted using targeted searches of PubMed/MEDLINE, EMBASE, Web of Science, and Google Scholar through June 2026. Search terms included combinations of “heel cord advancement,” “Achilles tendon advancement,” “anterior advancement of the tendo-Achillis,” “Murphy procedure,” “spastic equinus,” “equinus deformity correction,” “cerebral palsy,” “tendo-Achilles lengthening,” and “Achilles tendon lengthening.” Reference lists of relevant articles were also reviewed to identify additional studies. Studies were retained if they reported HCA-specific functional outcomes in pediatric patients with cerebral palsy and had a mean or typical follow-up of approximately 1 year or longer. Studies addressing ancillary radiographic, biomechanical, or technical effects of HCA without clinical or functional outcome assessment were not included in the primary clinical outcome synthesis but were considered for contextual discussion where relevant. When individual patients within an otherwise eligible cohort had less than 1 year of follow-up, this was noted as a limitation rather than used as a reason to exclude the entire study because doing so would have removed potentially relevant data from the limited HCA literature. Titles and abstracts were screened for relevance, followed by full-text reviews of potentially eligible studies. Non-English studies were reviewed using machine translation, and only data that could be clearly extracted were included.

Extracted variables included first author, publication year, country of origin, study design, sample size, number of treated limbs, patient age, sex, distribution of cerebral palsy involvement, Gross Motor Function Measure (GMFM) scores when reported, surgical technique, adjunctive procedures, postoperative immobilization and bracing, duration of follow-up, clinical outcome definitions, objective gait-analysis measures, functional outcomes, recurrence, overcorrection, calcaneal gait, increased knee flexion, crouch-related outcomes, and other reported complications. Because of the small number of available studies, heterogeneous patient populations, inconsistent outcome definitions, variable use of adjunctive procedures, and limited objective preoperative and postoperative gait data, formal meta-analysis was not performed and findings were synthesized descriptively. Attention was given to methodological limitations within each study, including retrospective de-

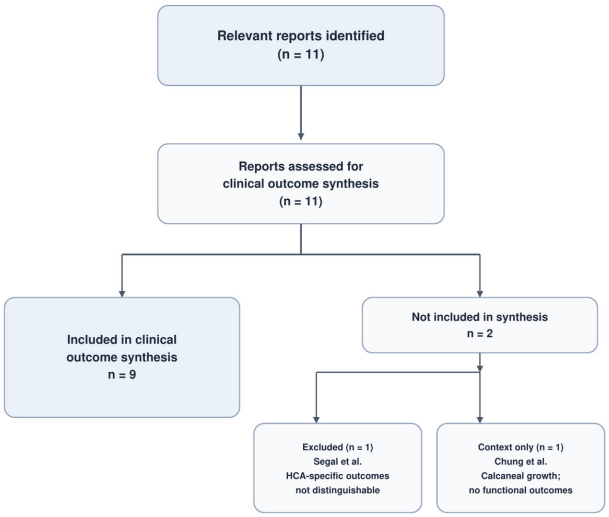

Figure 2. Flow diagram of study selection for the narrative review of heel cord advancement (HCA) in pediatric cerebral palsy. Of 11 relevant reports identified, nine were included in the clinical outcome synthesis. One study was excluded because HCA-specific outcomes could not be distinguished from those of other surgical procedures, and one radiographic study was retained for contextual discussion of HCA on calcaneal growth.

sign, lack of randomization, incomplete standardized functional assessment, limited or absent instrumented gait-analysis data, short or variable follow-up, and potential underreporting of recurrence, overcorrection, and crouch-related complications. Given the narrative nature of this review, methodological limitations were evaluated descriptively rather than through a formal risk-of-bias assessment using a standardized instrument.

2. OVERVIEW OF PUBLISHED STUDIES ON HCA

A total of 11 reports were identified as relevant to HCA in children with cerebral palsy; nine met the inclusion criteria for descriptive review.[17,22-29] One study was excluded because outcomes specific to HCA could not be distinguished from other lengthening procedures,[30] and one radiographic study without functional outcomes was retained for contextual discussion.[31] Of the nine included studies, seven were published in English, one in Korean, and one in Spanish. Non-English studies were reviewed using machine translation, and only data that could be clearly extracted were included. The study selection process is summarized in Figure 2.

The existing literature spans over four decades, with most studies published before the widespread adoption of contemporary standards for instrumented gait analysis, standardized functional outcome measures, and gross motor function classification outcomes in cerebral palsy research. Only two of the included studies were published within the past twenty years.[28,29] Most studies were retrospective case series or retrospective comparative cohorts; only one prospective comparative study was identified.[27] Objective preoperative and postoperative gait-analysis data were limited, and many studies relied primarily on clinical gait descriptions or subjective outcome categories such as excellent, good, or poor.

Adjunctive gastrocnemius recession was performed routinely in some cohorts and selectively in others when neutral dorsiflexion could not be achieved with HCA alone.[23,26,28] This procedural variability limits the ability to isolate the independent effect of HCA. Three studies directly compared HCA with tendo-Achilles lengthening or other related calf-lengthening procedures.[17,27,29] However, interpretation of these comparisons is constrained by small sample sizes, nonrandomized treatment allocation, differences in patient age and baseline function, variable follow-up durations, and inconsistent reporting of cerebral palsy distribution and GMFM score. One study evaluated HCA as a revision procedure after recurrent equinus following prior surgical correction.[24]

In summary, the literature on HCA constitutes low-level evidence. While the published studies offer valuable historical and technical insights, their capacity to support conclusions regarding comparative effectiveness, preservation of push-off strength, recurrence risk, overcorrection, or crouch-related outcomes is limited by retrospective study designs, heterogeneous patient populations, inconsistent outcome definitions, incomplete GMFM reporting, and limited objective gait-analysis or kinetic data.

2.1. DESCRIPTION OF HCA SURGICAL TECHNIQUE

Heel cord advancement (HCA) has been described with several technical variations, although the underlying principle is consistent. The Achilles tendon is detached from its posterior calcaneal insertion and reattached more anteriorly to reduce the plantarflexion moment arm.[17-19,32] The procedure is generally performed through a posterior or posteromedial approach to the distal Achilles tendon. After exposure, the tendon is mobilized and detached from the calcaneus as distally as possible while avoiding injury to the calcaneal apophysis (Figures 3a and 3b).

Osseous tunnels are created through the medial and lateral aspects of the calcaneus (Figure 3c). Sutures are placed in the distal tendon, typically using a Krackow stitch, passed through the osseous tunnels, and secured over the superior calcaneus (Figure 3d). A groove is subsequently created on the superior calcaneus immediately posterior to the subtalar joint, to accommodate the advanced tendon (Figure 3e). Most authors recommended routing the Achilles tendon anterior to the flexor hallucis longus muscle/tendon to reduce the risk of migration toward its original insertion (Figures 3d and 3e).

Technical modifications have included excision of a portion of the plantaris tendon and creation of lateral Achilles tendon flaps, or “dog ears,” to increase functional tendon length.[22] Earlier descriptions frequently used plantar button fixation, whereas later techniques used alternative fixation methods over the superior calcaneus to reduce plantar skin irritation.[18,28]

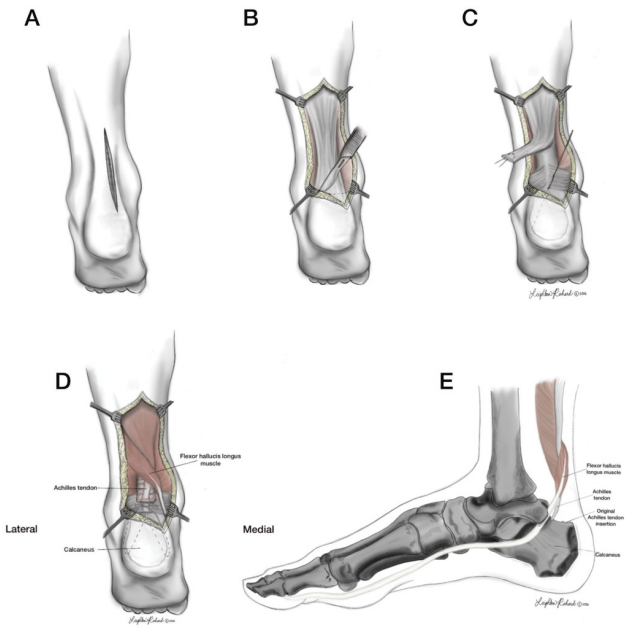

Figure 3. The Achilles tendon is exposed (a) and detached (b) from its calcaneal insertion. Osseous tunnels are created with a drill or Keith needle for suture passage (c). Krackow sutures are placed in the distal Achilles tendon, passed through osseous tunnels to exit the medial and lateral calcaneal cortices, and secured over the superior calcaneus, with the Achilles tendon routed and fixed anterior to the flexor hallucis longus muscle/tendon (d). A groove is created in the superior calcaneus immediately posterior to the subtalar joint, and the Achilles tendon is routed anterior to the flexor hallucis longus muscle/tendon and anchored within the groove (e).

Adjunctive gastrocnemius or gastrocsoleus recession was performed in some cohorts when neutral dorsiflexion could not be achieved with HCA alone.[23,26,28] Consequently, outcomes from these studies cannot always be attributed to isolated HCA. Historical biomechanical models proposed that anterior advancement decreases the plantarflexion moment arm while preserving a greater proportion of the late-stance push-off lever arm; however, this proposed advantage has not been adequately validated using contemporary gait-analysis or kinetic data.

Technical factors may contribute to unsuccessful outcomes. Inadequate advancement, tendon migration, or fixation failure may contribute to recurrent equinus, whereas excessive weakening of the plantarflexor lever arm may contribute to calcaneal gait, reduced push-off, increased knee flexion during stance, or progression toward crouch gait.[13,25,33]

2.2. STUDY DESIGN AND PATIENT CHARACTERISTICS

The included studies were primarily retrospective case series or retrospective comparative cohorts, with only one prospective comparative study identified.[27] Sample sizes ranged from 9 to 100 patients, representing 359 patients treated with HCA across the included literature. The weighted mean patient age was approximately 6.8 years, although age, sex distribution, CP subtype, and baseline functional status were inconsistently reported across studies (Table 1).

Patterns of CP involvement were reported in most studies, with diplegia representing the most common presentation, followed by hemiplegia and quadriplegia. For descriptive purposes, hemiplegia and monoplegia were considered unilateral involvement, whereas diplegia, paraplegia, quadriplegia, and double hemiplegia were considered bilateral involvement. Using this approach, CP distribution could be estimated for 311 of 359 HCA patients, including 104 with unilateral and 207 with bilateral involvement.

Standardized functional assessment was also infrequently reported and most studies did not include preoperative and postoperative gross motor function measurements. Engsberg et al. was the principal exception, prospectively evaluating GMFM outcomes in addition to ankle range of motion and gait measures.[27] The GMFM is a criterion-referenced instrument developed to detect changes in gross motor function in children with cerebral palsy.[34]

Several studies incorporated adjunctive procedures, most commonly gastrocnemius recession, when neutral dorsiflexion could not be achieved with HCA alone.[23,26,28] Three studies directly compared HCA with tendo-Achilles lengthening (TAL),[17,27,29] and one evaluated HCA as a revision procedure following unsuccessful prior surgical correction.[24] Overall, the available literature is characterized by predominantly retrospective study designs, heterogeneous patient populations, inconsistent functional assessment, and variable use of adjunctive procedures, limiting the ability to isolate the independent effects of HCA.

2.3. POSTOPERATIVE IMMOBILIZATION, CASTING, AND BRACING

Postoperative immobilization and bracing protocols were inconsistently reported across the included studies (Table 2). Among studies that described postoperative management, most used cast immobilization for approximately 4–6 weeks after HCA. Short-leg casting was most reported, although some authors used long-leg casting, particularly in earlier series and revision settings.[24,25] When ankle position was specified, immobilization was typically performed in neutral or slight plantarflexion to protect the advanced Achilles tendon insertion while maintaining correction.

Following cast removal, several studies recommended ankle-foot orthoses (AFOs), although duration, ankle position, and permitted weight bearing varied. Strecker et al. used an AFO with dorsiflexion and plantarflexion stops for 3 months, followed by nighttime AFO use for an additional 3 months.[23] Yoshimoto et al. prescribed AFO use with the ankle in neutral alignment for 3 months.[26] Engsberg et al. used an AFO with dorsiflexion and plantarflexion stops for 23 hours per day for 3 months, followed by nighttime use for an additional 3 months.[27] Other reports provided limited or no detail regarding postoperative orthotic management.

Table 1. Demographics of published studies of HCA. CP distribution terms were retained as reported by the original authors. Abbreviations: HCA, heel cord advancement; TAL, tendo-Achilles lengthening; Vulpius, gastrocnemius–soleus recession; Strayer, distal gastrocnemius recession; White, tendo-Achilles lengthening; NR, not reported; yr, year; M, male; F, female; GMFM-dimensions D,E, gross motor function measure standing; walking, running, and jumping; Quad, quadriplegia/quadriparesis; Hemi, hemiplegia/hemiparesis; Para, paraplegia/paraparesis; Di, diplegia; mono, monoparesis.

Study	Procedure	Patients (limbs)	Demographics Avg. age (range) males/females	GMFM reported	CP distribution
Pierrot (1974)	HCA	23 (32)	6.2yr (2.9yr – 9.6yr) 14m/9f	NR	8 Quad 9 Hemi 5 Para 1 Mono
	TAL	18 (22)	7.1 yr (3.3yr – 10.2yr) 9m/9f		5 Quad 7 Hemi 4 Para 2 Mono
Throop (1975)	HCA	48 (79)	NR	NR	NR
Strecker (1990)	HCA + Vulpius in 46 pt.	100 (161)	6.5yr (1yr-10yr) NR	NR	4 Quad/ double hemi 37 Hemi 59 Di
Lee (1991)	HCA	23 (36)	7.9 yr (2.9yr – 13.7yr) 13m/10f	NR	1 Quad 1 Hemi 20 Para 1 Mono
Walker (1994)	HCA	90 (122)	NR (75 ≤ 10yr; 15 > 10yr) 54m/36f	NR	24 Quad 29 Hemi 37 Di
Yoshimoto (2005)	HCA + Vulpius	17 (20)	10 yr (5yr-17yr) 9m/8f	NR	11 Hemi 6 Di
Engsberg (2005)	HCA	12 (NR)	4.3 yr 7m/5f	GMFM-dimension D,E	12 Di
	Vulpius	10 (NR)	6.8 yr 4m/6f		10 Di
	White	10 (NR)	8.6 yr 8m/2f		10 Di
Sycheuski (2007)	HCA +/- Strayer or Vulpius	37 (54)	6.7 yr (3-14yr) NR	NR	2 Quad 12 Hemi 23 Di
Rocha (2018)	HCA	9 (12)	7.5 yr (3.2-14yr) 7m/2f	NR	3 Hemi 6 Di
	TAL	9 (13)	6.6 yr (3.11-9.6yr) 5m/4f		3 Hemi 6 Di

Due to the lack of standardization in postoperative immobilization, weight-bearing progression, rehabilitation, and orthotic protocols, direct comparison across studies is limited. Variables such as brace adherence, rehabilitation intensity, and the impact of postoperative management on maintenance of correction were not systematically evaluated. Consequently, the current literature provides only a descriptive summary of postoperative care following HCA and does not support definitive conclusions regarding the optimal duration of casting, timing of weight bearing, or the most effective AFO protocol.

3. CLINICAL OUTCOMES

Clinical outcomes following heel cord advancement were inconsistently reported across studies, encompassing subjective gait classifications, ambulatory status, ankle dorsiflexion, selected radiographic measures, GMFM scores, and a limited set of instrumented gait-analysis variables. Definitions of success, recurrence, overcorrection, and poor outcomes varied considerably. Most studies did not utilize standardized functional measures, GMFM score, or objective preoperative and postoperative gait analysis. While several reports noted postoperative improvements in gait pattern, ankle dorsiflexion, or ambulatory status, these re-

Table 2. Summary of postoperative immobilization, casting and bracing protocols. HCA, heel cord advancement; TAL, tendo-Achilles lengthening; Vulpius, gastrocnemius–soleus recession; Strayer, distal gastrocnemius recession; White, tendo-Achilles lengthening; NR, not reported; wk, week; LL, long leg cast; SL, short leg cast; df, dorsiflexion; pf, plantarflexion; AFO, ankle-foot orthosis; w, with; w/o, without.

Study	Procedure	Casting	Bracing
Pierrot (1974)	HCA	6 wk	19 pt: < 12mo; 10pt: >12mo
	TAL	NR	9 pt: <12 mo; 11 pt: >12 mo
Throop (1975)	HCA	6 wk SL	6 mo SL
Strecker (1990)	HCA + Vulpius (in 46%)	6 wk SL	3 mo AFO w/ 10° df and pf stops, 3 mo AFO at night
Lee (1991)	HCA	6 wk LL w/ ankle in 15° pf, 4 wk SL cast in neutral	To address over- or under correction of equinus as needed
Walker (1994)	HCA	6 wk LL w/ knee 90° flex and ankle in15° pf	Variable
Yoshimoto (2005)	HCA + Vulpius	6 wk SL w/ ankle in neutral and non-weightbearing	3 mo AFO w/ ankle in neutral and partial weightbearing
Engsberg (2005)	HCA	6 wk SL and non-weightbearing	3 mo AFO with 10° df/ pf stops for 23 hours/day, followed by 3 mo AFO at night
	Vulpius	5 wk SL w/ 5° ankle df	AFO with df and pf stops
	White	4 wk SL walking cast w/ ankle in neutral	AFO w/o pf and free df daytime only
Sycheuski (2007)	HCA +/- Strayer or Vulpius	6 wk split plaster cast	NR
Rocha (2018)	HCA	NR	
	TAL	NR	AFO in failed surgical cases

sults require cautious interpretation. Most studies were retrospective and uncontrolled, with variable follow-up durations, inconsistent adjunctive procedures, and limited capacity to account for maturation, rehabilitation, baseline functional status, or concomitant surgeries.

Follow-up ranged from approximately 1 to 9.7 years among studies included in the clinical outcome synthesis, with longer follow-up available primarily from older retrospective series. Because most studies relied on nonstandardized clinical assessment rather than validated functional measures or instrumented gait analysis, the available outcomes are best interpreted as descriptive summaries of reported experience with HCA rather than evidence of comparative effectiveness (Table 3).

3.1. GAIT CLASSIFICATION OUTCOMES

In four studies, postoperative gait outcomes were reported using qualitative categories such as excellent, good, or poor. Excellent outcomes generally reflected a heel-toe gait pattern without knee hyperextension and with preserved push-off, good outcomes reflected a flat-foot gait with or without push-off, and poor outcomes included persistent or recurrent toe-heel gait or calcaneal gait.[17,22,24,25] Across 269 limbs treated in these four studies, approximately 77% were classified as having excellent or good outcomes and 23% as having poor outcomes. Although these findings suggest that many patients achieved clinically favorable gait patterns after HCA, the result should be interpreted cautiously because the underlying studies used subjective outcome definitions, differed in follow-up duration, and frequently lacked standardized functional assessment or objective gait analysis.

HCA was combined with gastrocnemius or gastrocsoleus recession in some cohorts when neutral dorsiflexion could not be achieved with HCA alone,[23,28] further limiting attribution of postoperative gait outcomes solely to HCA in some cases. In addition, it potentially indicates that HCA may not be sufficient as an isolated intervention in all cases. Longer-term follow-up appeared to reveal more recurrent equinus and poor outcomes than shorter-term studies, suggesting that early postoperative results may underestimate late failure.[25] The available gait classification data provide limited evidence of favorable clinical outcomes but do not establish the comparative effectiveness or long-term durability of HCA.

3.2. FUNCTIONAL OUTCOMES

Functional outcomes were assessed using ambulatory status, clinical descriptions of walking ability, range-of-motion measurements, radiographic alignment, GMFM scores, and selected gait-analysis variables.[23-29] However, outcome

Table 3. Summary of reported clinical outcomes following heel cord advancement. Abbreviations: HCA, heel cord advancement; TAL, tendo-Achilles lengthening; Vulpius, gastrocnemius–soleus recession; Strayer, distal gastrocnemius recession; White, tendo-Achilles lengthening; E, excellent; G, good; P, poor; tp, tibioplantar angle; ft., foot; aROM, active range of motion; pROM, passive range of motion; GMFM, gross motor function measure; yr, year.

Study	Procedure	Results	Avg. Follow Up (range)
Pierrot (1974)	HCA	9% E; 66% G; 25% P	6.16 yr (3.5 -13.1 yr)
	TAL	9% E; 45.5% G; 45.5% P	6.83 yr
Throop (1975)	HCA	17.7% E; 72.2% G; 10.1% P	1-4 yr
Strecker (1990)	HCA + Vulpius (in 46%)	61% E; 37% G; 2% P	4.5 yr (2.5-6.33yr)
Lee (1991)	HCA	33.4% E; 58.3% G; 8.3% P ↑df	2.7 yr (1-3.7 yr)
Walker (1994)	HCA	11% E; 53% G; 35% P	9.7 yr (2yr-20yr)
Yoshimoto (2005)	HCA + Vulpius	↓tp angle and foot callosity 7 pt. gained ability to stand on affected ft.	8 yr (5.83-9.9 yr)
Engsberg (2005)	HCA	↑aROM and pROM; ↑GMFM standing and walking/running/jumping scores and their combined average; ↑gait speed and stride length, improved ankle df during gait	1.17 yr (.92-1.4 yr)
	Vulpius	↑aROM and pROM ; ↑GMFM combined average score; insignificant changes to gait speed, cadence, and stride length; ↑df at initial contact	1.17 yr (.92-1.4 yr)
	White	↑aROM and pROM ; ↑GMFM standing and combined average score; insignificant speed and stride length changes, decreased cadence; ↑df at initial contact.	1.17 yr (.92-1.4 yr)
Sycheuski (2007)	HCA +/- Strayer or Vulpius	75% E; 20% G; 5% P	3.83 yr (.25 -8yr)
Rocha (2018)	HCA	91.7% success rate	4.1 yr (2.1-5.8yr)
	TAL	38.3% success rate	3.8 yr (2.1-5.9yr)

measures and definitions varied across studies, and most reports did not use standardized functional assessments.

Ambulatory status was reported in five studies comprising 267 patients.[23-26,28] Across these cohorts, 169 patients (63.3%) were categorized as unassisted or ambulatory preoperatively compared with 207 (77.5%) postoperatively, while the number classified as nonambulatory decreased from 25 (9.4%) to 3 (1.1%). The number requiring assistance or an orthosis decreased from 73 (27.3%) to 57 (21.3%). However, definitions of ambulatory status and use of assistive devices or orthoses were not standardized across studies. In addition, these largely uncontrolled cohorts did not adequately account for maturation, rehabilitation, postoperative orthotic management, baseline functional status, or concomitant procedures. These aggregate changes should be interpreted descriptively and cannot establish that HCA independently improved ambulatory function.

Engsberg et al. provided the most detailed standardized functional and gait-related assessment. In this prospective, nonrandomized comparative study, 32 children with spastic diplegic cerebral palsy, all classified as GMFCS level I, underwent one of three isolated heel cord procedures, HCA, White-TAL, and Vulpius gastrocsoleus recession.[27] The HCA group included only 12 patients, had a mean age of 4.3 years, and was followed for approximately 14 months. The HCA group demonstrated significant postoperative improvements in GMFM standing and walking, running, and jumping scores, as well as active and passive ankle dorsiflexion and selected gait variables. Importantly, the investigators noted that the observed improvement in GMFM scores was within the range expected from maturation for children of similar age and GMFCS level, limiting the ability to attribute these changes independently to HCA.

Other studies have reported improvements in ankle dorsiflexion, tibioplantar angle, weight-bearing alignment, and the ability to stand on the affected foot.[24,26,29] These findings were inconsistently reported and were generally not paired with validated functional assessments or instrumented gait analysis. Overall, the available literature documents selected postoperative functional improvements, but

the independent effect of HCA on functional mobility remains uncertain.

3.3. COMPLICATIONS AND RECURRENCE

Reporting of complications following HCA was inconsistent across studies, with varying definitions of recurrence, overcorrection, calcaneal gait, and poor outcomes.[17,22-26,28,29] Among the four studies that categorized gait outcomes as excellent, good, or poor, approximately 23% of 269 treated limbs were classified as poor outcomes, with recurrent equinus accounting for many of these failures.[17,22,24,25]

The 23% rate of poor outcomes after HCA offers a contextual benchmark for comparison with unfavorable outcomes reported after other procedures for spastic equinus. However, the actual failure rate of HCA remains uncertain due to heterogeneous outcome definitions, variable follow-up durations, and potential underreporting of adverse events, which limit direct comparison across procedures. For Achilles tendon lengthening (percutaneous TAL or Z-Achillotenotomy), Kérő et al. reported recurrent equinus requiring repeat surgery in 21.3% of 347 procedures at a mean 15-year follow-up, with overcorrection in 3.5%.[35] In contrast, Chung et al. reported recurrent equinus in 9.1% of 243 patients post-TAL at a mean follow-up of 8.1 years.[36] Following the Baumann gastrocnemius recession, Svehlík et al. observed recurrent equinus in 23.8% and overcorrection in 9.5% at 10 years,[37] while Firth et al. reported 35% recurrent equinus and 2.5% overcorrection after distal gastrocnemius or gastrocsoleus recession at a mean 7.5-year follow-up.[38] More recently, Galicia-Zamalloa et al. reported recurrent equinus in 16.7% (4 of 24 children) following Vulpius gastrocnemius recession.[39] In a 2025 register-based study of 184 children undergoing isolated gastrocsoleus lengthening, Lindén et al. reported repeat gastrocsoleus surgery in 15% following percutaneous TAL, 8.7% following open TAL, and 16% following gastrocnemius or gastrocsoleus lengthening, which primarily included Baker, Vulpius, and Baumann procedures.[40] These findings indicate that recurrence, reoperation, and other unfavorable outcomes are relevant across procedures. Nevertheless, differences in patient selection, operative technique, cerebral palsy subtype, follow-up duration, definitions of failure, and the accuracy of HCA failure rates limit direct comparison with HCA.

Recurrence appeared to increase with duration of follow-up. Longer-term series reported a greater accumulation of recurrent equinus and poor outcomes, whereas studies with shorter follow-up generally reported fewer failures.[24,25] This pattern suggests that short-term follow-up may underestimate late recurrence. However, because most studies relied on clinical observation rather than standardized definitions or instrumented gait analysis, the true incidence and timing of recurrent equinus after HCA remain uncertain.

Overcorrection was reported less frequently than recurrence and was typically characterized as calcaneal gait.[17,24] The true frequency of overcorrection may be underestimated because most HCA studies were retrospective, follow-up was variable, and few incorporated objective sagittal-plane gait analysis capable of identifying postoperative increases in knee flexion or progression toward crouch gait. Postoperative increases in knee flexion during stance and progression toward crouch gait were not systematically evaluated. Consequently, the lack of reported calcaneal gait or crouch-related deterioration in individual series should not be interpreted as evidence that these complications did not occur.

Strecker et al. reported no recurrent equinus or calcaneal gait in 100 patients and 161 treated limbs.[23] Although this represents one of the largest published HCA cohorts, outcomes were assessed clinically, without standardized functional measures or objective preoperative and postoperative gait analysis. These findings should therefore be interpreted cautiously.

Technical factors have been identified as potential contributors to unsuccessful outcomes, such as inadequate tendon advancement, tendon migration, fixation failure, or errors in tendon routing.[17,22] Minor postoperative complications, including pressure-related skin problems resulting from casting or orthotic use, have also been reported but typically resolve without long-term sequelae.[24]

An additional consideration in skeletally immature patients is the potential effect of HCA on calcaneal growth. Chung et al. reported significant reductions in posterior calcaneal length and in the posterior-to-total calcaneal length ratio after HCA in seven children with unilateral spastic cerebral palsy, suggesting preferential reduction in posterior calcaneal growth.[31] The authors proposed that loss of physiologic Achilles tendon traction on the posterior calcaneal apophysis may contribute to this effect and considered the finding sufficient reason to discontinue routine use of HCA. However, the study did not evaluate the functional or long-term clinical consequences of these radiographic changes.

In summary, recurrent equinus remains the most consistently reported complication following HCA, whereas the risks of overcorrection, calcaneal gait, crouch-related gait deterioration, and long-term effects on bone growth remain insufficiently characterized.

3.4. PREDICTORS OF OUTCOMES

Predictors of outcome following HCA were evaluated inconsistently and were derived primarily from retrospective subgroup analyses rather than prespecified multivariable models.[25,28,29] Reported associations should be considered exploratory rather than definitive. Most studies did not provide standardized baseline functional measures or objective gait parameters, limiting identification of reliable patient-level predictors.

Baseline ambulatory function and the distribution of cerebral palsy involvement were identified as the most frequently discussed patient-related factors.[25,28] Walker et al. reported that patients with better preoperative ambulatory function and diplegic involvement experienced more favorable outcomes, while those with poorer baseline function and more extensive motor involvement had less favorable results.[25] Although some studies suggested an association between older age and improved outcomes, this relation-

ship was not consistently observed after adjustment, suggesting that baseline function and patient characteristics may be more significant determinants than chronological age alone.[25,28]

Procedure-related factors were also described but were not systematically evaluated. Adequate tendon advancement, secure fixation, and prevention of tendon migration were considered important technical factors.[17,22] Gastrocnemius or gastrocsoleus recession was added in some cohorts when neutral dorsiflexion could not be achieved with HCA alone.[23,26,28] However, these studies did not identify preoperative clinical, functional, or patient-related factors that predicted which patients would require an adjunctive recession or would fail to achieve adequate correction with isolated HCA. Consequently, the available literature does not provide criteria for predicting when HCA alone will be insufficient.

Published studies do not permit reliable identification of predictors of success or failure following HCA. In particular, the influence of baseline ambulatory function, unilateral versus bilateral involvement, plantarflexor weakness, sagittal-plane knee mechanics, and preexisting crouch tendency remains insufficiently characterized.

3.5. DIRECT COMPARISON WITH OTHER PROCEDURES

Three studies directly compared HCA with tendo-Achilles lengthening (TAL) or related calf-lengthening procedures.[17,27,29] These reports described similar or, in selected cohorts, more favorable clinical outcomes following HCA. However, interpretation is limited by small sample sizes, nonrandomized treatment allocation, differences in patient age and baseline function, variable follow-up duration, and inconsistent reporting of cerebral palsy characteristics.

The rationale for HCA is that anterior advancement of the Achilles tendon insertion reduces the plantarflexion moment arm without formal tendon lengthening.[17-19] This approach is intended to correct equinus while preserving a greater proportion of late-stance push-off. However, this theoretical benefit has not been sufficiently evaluated using contemporary instrumented gait analysis, ankle kinetics, or plantarflexor power measurements. Engsberg et al. reported that HCA was associated with improvements in ankle dorsiflexion and selected gait measures; however, the HCA cohort was significantly younger than the comparison groups, and the investigators attributed at least some observed functional and gait improvement to maturation rather than the surgical procedure itself.[27]

Patient selection may influence outcomes differently following HCA and TAL. Within the HCA literature, Walker et al. reported significantly better outcomes in patients with diplegia, suggesting that CP distribution may influence HCA outcomes.[25] In contrast, Borton et al., in a series of 195 isolated calf-lengthening procedures using percutaneous TAL, open Z-lengthening, or Baker gastrocsoleus aponeurotic lengthening, reported only 42% satisfactory outcomes overall, with 22% recurrent equinus and 36% calcaneus.[41] The pattern of failure varied according to CP distribution: patients with hemiplegia experienced a 38% rate of recurrent equinus but only 4% calcaneus, whereas children with diplegia operated on at 8 years of age or younger had a 44% risk of calcaneus compared with 19% in those older than 8 years. Percutaneous TAL was particularly unpredictable in diplegia, with only 38% achieving a satisfactory result. Similarly, Dietz et al. reported substantially greater postoperative triceps surae overweakening after TAL in patients with diplegia and quadriplegia than in those with hemiplegia.[42] Collectively, these findings indicate that CP distribution may influence not only the likelihood of an unfavorable outcome but also whether failure manifests predominantly as recurrent equinus or overcorrection. However, current literature does not establish whether HCA provides an advantage over TAL for any specific CP subtype.

Overall, current evidence does not demonstrate that HCA reduces recurrence, preserves push-off more effectively, or lowers the risk of overcorrection or crouch compared with TAL.

SUMMARY AND CONCLUSION

Heel cord advancement is a historically distinct surgical intervention for spastic equinus in cerebral palsy, although its current clinical role remains unclear. Existing studies indicate that HCA may improve ankle alignment and gait in selected patients; however, the supporting evidence is constrained by predominantly retrospective study designs, heterogeneous patient populations, inconsistent outcome definitions, frequent concomitant procedures, and limited use of standardized functional or instrumented gait assessments. The hypothesized biomechanical benefit of HCA, which involves reducing the plantarflexion moment arm while maintaining late-stance push-off, has not been substantiated through contemporary gait analysis, ankle kinetics, or plantarflexor power measurements. Additionally, decreasing plantarflexion leverage may impair tibial control and potentially increase knee flexion or contribute to crouch gait in susceptible individuals.

Recurrent equinus is the most consistently reported adverse outcome following HCA, while overcorrection, calcaneal gait, crouch-related deterioration, and the impact on plantarflexor power are insufficiently characterized. Current evidence does not establish reliable criteria for patient selection or demonstrate that HCA is superior to tendo-Achilles lengthening or gastrocnemius–soleus recession. Consequently, HCA should be considered an incompletely evaluated alternative rather than a biomechanically superior procedure. Future prospective comparative studies that incorporate standardized functional classification, instrumented gait analysis, ankle kinetics, knee kinematics, and long-term follow-up are necessary to clarify its clinical role. Until such evidence is available, surgical decision-making should be individualized and based on the overall sagittal-plane gait pattern, rather than the theoretical mechanical advantage of HCA alone.

ACKNOWLEDGEMENTS

The authors would like to thank Hiram Rogers, Director of Library Services at the Edward Via College of Osteopathic Medicine (VCOM)–Auburn Campus, for his assistance in locating and obtaining full-text articles relevant to this review.

AUTHOR CONTRIBUTIONS

Daniel Cawley developed the study idea and design, organized and managed the data, analyzed and interpreted the results, helped develop the study methods, coordinated and supervised the project, checked the accuracy of the work, and drafted and revised the manuscript.

Leighton Richard organized and managed the data, analyzed and interpreted the results, checked the accuracy of the work, created all figures and illustrations, and drafted and revised the manuscript.

William Brophy organized and managed the data, analyzed and interpreted the results, helped develop the study methods, checked the accuracy of the work, and drafted and revised the manuscript.

Luis Rodriguez Anaya analyzed and interpreted the results, coordinated and supervised the project, checked the accuracy of the work, and drafted and revised the manuscript.

CONFLICT OF INTEREST STATEMENT

The authors declare no conflicts of interest related to this work.

FUNDING

No funding was received for the preparation of this manuscript.

DECLARATION OF GENERATIVE AI AND AI-ASSISTED TECHNOLOGIES IN THE MANUSCRIPT PREPARATION PROCESS

During the preparation of this work the authors used ChatGPT (OpenAI, GPT-5.3 model; OpenAI, San Francisco, CA, USA) to assist with language editing and manuscript condensation. The authors subsequently reviewed and edited all AI-assisted content and take full responsibility for the content of the manuscript.

Submitted: August 11, 2026 EST. Accepted: November 07, 2026 EST. Published: November 22, 2026 EST.

REFERENCES

1. Kedem P, Scher DM. Foot deformities in children with cerebral palsy. *Curr Opin Pediatr*. 2015;27(1):67-74. doi:10.1097/MOP.0000000000000180

2. Horsch A, Klotz MCM, Platzer H, Seide SE, Ghandour M. Recurrence of equinus foot in cerebral palsy following its correction—a meta-analysis. *Children (Basel)*. 2022;9(3):339. doi:10.3390/children9030339. PMID:35327713

3. Chakraborty S, Nandy A, Kesar TM. Gait deficits and dynamic stability in children and adolescents with cerebral palsy: a systematic review and meta-analysis. *Clin Biomech (Bristol)*. 2020;71:11-23. doi:10.1016/j.clinbiomech.2019.09.005

4. Noorkoiv M, Lavelle G, Theis N, et al. Predictors of walking efficiency in children with cerebral palsy: lower-body joint angles, moments, and power. *Phys Ther*. 2019;99(6):711-720. doi:10.1093/ptj/pzz041. PMID:31155663

5. Ballaz L, Plamondon S, Lemay M. Ankle range of motion is key to gait efficiency in adolescents with cerebral palsy. *Clin Biomech (Bristol)*. 2010;25(9):944-948. doi:10.1016/j.clinbiomech.2010.06.011

6. Nardon M, Ruzzante F, O'Donnell L, Adami A, Dayanidhi S, Bertucco M. Energetics of walking in individuals with cerebral palsy and typical development, across severity and age: a systematic review and meta-analysis. *Gait Posture*. 2021;90:388-407. doi:10.1016/j.gaitpost.2021.09.190

7. Lee J, Suk MH, Yoo S, Kwon JY. Physical activity energy expenditure predicts quality of life in ambulatory school-age children with cerebral palsy. *J Clin Med*. 2022;11(12):3362. doi:10.3390/jcm11123362. PMID:35743433

8. Esterley M, Krach LE, Pederson K, Wandersee NG, Tierney SC, Boyer ER. Physical and psychosocial consequences of falls in ambulatory individuals with cerebral palsy by age and gross motor function. *Arch Phys Med Rehabil*. 2025;106(5):688-695. doi:10.1016/j.apmr.2024.12.010

9. Klaewkasikum K, Patathong T, Woratanarat P, et al. Efficacy of conservative treatment for spastic cerebral palsy children with equinus gait: a systematic review and meta-analysis. *J Orthop Surg Res*. 2022;17(1):411. doi:10.1186/s13018-022-03301-3. PMID:36076293

10. Zahran DAE, Bahr WM, Abd Elazim FH. Systematic review: exercise training for equinus deformity in children with cerebral palsy. *Bull Fac Phys Ther*. 2022;27:37. doi:10.1186/s43161-022-00093-9

11. Blumetti FC, Belloti JC, Tamaoki MJ, Pinto JA. Botulinum toxin type A in the treatment of lower limb spasticity in children with cerebral palsy. *Cochrane Database Syst Rev*. 2019;10(10):CD001408. doi:10.1002/14651858.CD001408.pub2. PMID:31591703

12. Lintanf M, Bourseul JS, Houx L, Lempereur M, Brochard S, Pons C. Effect of ankle-foot orthoses on gait, balance and gross motor function in children with cerebral palsy: a systematic review and meta-analysis. *Clin Rehabil*. 2018;32(9):1175-1188. doi:10.1177/0269215518771824

13. Shore BJ, White N, Graham HK. Surgical correction of equinus deformity in children with cerebral palsy: a systematic review. *J Child Orthop*. 2010;4(4):277-290. doi:10.1007/s11832-010-0268-4. PMID:21804889

14. Horsch A, Petzinger L, Deisenhofer J, et al. The impact of operative correction of equinus in cerebral palsy on gait patterns. *Foot Ankle Int*. 2024;45(2):130-140. doi:10.1177/10711007231217273

15. Brunner R, Frigo CA. Control of tibial advancement by the plantar flexors during the stance phase of gait depends on knee flexion with respect to the ground reaction force. *Bioengineering (Basel)*. 2024;11(1):41. doi:10.3390/bioengineering11010041. PMID:38247918

16. Esteve R. Un procédé d'équilibration des pieds spastiques. *La Vie Médicale*. 1970;1:51.

17. Pierrot AH, Murphy OB. Albert E. Klinkicht Award, 1972. Heel cord advancement: a new approach to the spastic equinus deformity. *Orthop Clin North Am*. 1974;5(1):117-126. doi:10.1016/S0030-5898(20)31246-3

18. Downey MS, McGlamry ED. Anterior advancement of the tendo Achillis. *J Am Podiatr Med Assoc*. 1987;77(3):117-122. doi:10.7547/87507315-77-3-117

19. Smith SD, Weil LS. Anterior advancement of the tendo Achillis for spastic equinus deformity. *J Am Podiatry Assoc*. 1974;64(12):1016-1023. doi:10.7547/87507315-64-12-1016

20. Theologis T. Lever arm dysfunction in cerebral palsy gait. *J Child Orthop*. 2013;7(5):379-382. doi:10.1007/s11832-013-0510-y. PMID:24432098

21. Hösl M, Kruse A, Tilp M, et al. Impact of altered gastrocnemius morphometrics and fascicle behavior on walking patterns in children with spastic cerebral palsy. *Front Physiol*. 2020;11:518134. doi:10.3389/fphys.2020.518134. PMID:33178029

22. Throop FB, DeRosa GP, Reeck C, Waterman S. Correction of equinus in cerebral palsy by the Murphy procedure of tendo calcaneus advancement: a preliminary communication. *Dev Med Child Neurol*. 1975;17(2):182-185. doi:10.1111/j.1469-8749.1975.tb03470.x

23. Strecker WB, Via MW, Oliver SK, Schoenecker PL. Heel cord advancement for treatment of equinus deformity in cerebral palsy. *J Pediatr Orthop*. 1990;10(1):105-108. doi:10.1097/01241398-199001000-00021

24. Lee DY, Choi IH, Chung CY, et al. Management of recurred spastic equinus deformity by heel cord advancement in cerebral palsy. *J Korean Orthop Assoc*. 1991;26(5):1480-1484. doi:10.4055/jkoa.1991.26.5.1480

25. Walker JL, Stevens DB, Clark NS, Opfell AR. Heel cord advancement in children with spastic equinus deformity. *Foot Ankle Int*. 1994;15(10):536-540. doi:10.1177/107110079401501003

26. Yoshimoto M, Kura H, Matsuyama T, Sasaki T, Yamashita T, Ishii S. Heel cord advancement combined with Vulpius' lengthening of the gastrocnemius. *Clin Orthop Relat Res*. 2005;(434):213-216. doi:10.1097/01.blo.0000155010.77961.8a

27. Engsberg JR, Oeffinger DJ, Ross SA, White HD, Tylkowski CM, Schoenecker PL. Comparison of three heel cord surgeries in children with cerebral palsy. *J Appl Biomech*. 2005;21(4):322-333. doi:10.1123/jab.21.4.322

28. Sycheuski L. Surgical treatment of equinus foot deformity in cerebral palsy patients. *J Vibroeng*. 2007;9(3):87-91.

29. Rocha GA, López Vázquez A, Hutchinson B, et al. El adelantamiento del tendón de Aquiles en comparación con el alargamiento fraccionado para la corrección del equino neuroespástico en pacientes pediátricos, un análisis retrospectivo. *Rev Mex Ortop Pediatr*. 2018;20(2):72-79.

30. Segal LS, Thomas SE, Mazur JM, Mauterer M. Calcaneal gait in spastic diplegia after heel cord lengthening: a study with gait analysis. *J Pediatr Orthop*. 1989;9(6):697-701. doi:10.1097/01241398-198911000-00013

31. Chung CY, Jo HC, Choi IH, Cho TJ, Lee DY. The effect of the heel cord advancement on the calcaneal growth in spastic cerebral palsy. *J Korean Orthop Assoc*. 1998;33(7):1774-1781. doi:10.4055/jkoa.1998.33.7.1774

32. Southerland JT, ed. *McGlamry's Comprehensive Textbook of Foot and Ankle Surgery*. 4th ed. Wolters Kluwer Health/Lippincott Williams & Wilkins; 2013.

33. Sutherland DH, Cooper L. The pathomechanics of progressive crouch gait in spastic diplegia. *Orthop Clin North Am*. 1978;9(1):143-154. doi:10.1016/S0030-5898(20)30887-7

34. Russell DJ, Rosenbaum PL, Cadman DT, Gowland C, Hardy S, Jarvis S. The gross motor function measure: a means to evaluate the effects of physical therapy. *Dev Med Child Neurol*. 1989;31(3):341-352. doi:10.1111/j.1469-8749.1989.tb04003.x

35. Kérő G, Frigyesi L, Szabó T, Than P, Vermes C. Long-term follow-up of achillotenotomy in patients with cerebral palsy. *Orv Hetil*. 2020;161(8):306-312. doi:10.1556/650.2020.31669

36. Chung CY, Sung KH, Lee KM, et al. Recurrence of equinus foot deformity after tendo-Achilles lengthening in patients with cerebral palsy. *J Pediatr Orthop*. 2015;35(4):419-425. doi:10.1097/BPO.0000000000000278

37. Svehlík M, Kraus T, Steinwender G, Zwick EB, Saraph V, Linhart WE. The Baumann procedure to correct equinus gait in children with diplegic cerebral palsy: long-term results. *J Bone Joint Surg Br*. 2012;94(8):1143-1147. doi:10.1302/0301-620X.94B8.28447

38. Firth GB, Passmore E, Sangeux M, et al. Multilevel surgery for equinus gait in children with spastic diplegic cerebral palsy: medium-term follow-up with gait analysis. *J Bone Joint Surg Am*. 2013;95(10):931-938. doi:10.2106/JBJS.K.01542

39. Galicia-Zamalloa AL, Gómez-Chavarria J, González-Ramírez R, Sánchez-Gómez VH. Gait analysis of kinematic changes after Vulpius gastrocnemius recession in children with spastic hemiplegic cerebral palsy and equinus deformity. *Cureus*. 2026;18(4):e107640. doi:10.7759/cureus.107640. PMID:42186612

40. Lindén O, Lauge-Pedersen H, Hägglund G, Wagner P. Development of ankle and knee range of motion after isolated gastrocsoleus lengthening in children with cerebral palsy: a register-based longitudinal cohort study. *Acta Orthop*. 2025;96:331-338. doi:10.2340/17453674.2025.43387. PMID:40242883

41. Borton DC, Walker K, Pirpiris M, Nattrass GR, Graham HK. Isolated calf lengthening in cerebral palsy: outcome analysis of risk factors. *J Bone Joint Surg Br*. 2001;83(3):364-370. doi:10.1302/0301-620X.83B3.0830364

42. Dietz FR, Albright JC, Dolan L. Medium-term follow-up of Achilles tendon lengthening in the treatment of ankle equinus in cerebral palsy. *Iowa Orthop J*. 2006;26:27-32.