Shayakhanov S, Konkayev A, Smagulova Z, Konkayeva M. PERIOPERATIVE REMOTE ISCHEMIC PRECONDITIONING IN THREE OLDER ADULTS UNDERGOING ORTHOPEDIC AND SPINE SURGERY. *Orthopedic Reviews*. Published online November 24, 2026. doi:10.52965/001c.175660

General

PERIOPERATIVE REMOTE ISCHEMIC PRECONDITIONING IN THREE OLDER ADULTS UNDERGOING ORTHOPEDIC AND SPINE SURGERY

Shamil Shayakhanov, M.D.[1], Aidos Konkayev, Doctor of Medical Sciences, Full Professor[2,3], Zauresh Smagulova, M.D.[4], Maiya Konkayeva, M.D.[4]

[1] Karaganda Medical University, [2] Anesthesiology, Intensive Care and Emergency Medical Care, Astana Medical University, [3] Anesthesiology and Intensive Care, National Scientific Center of Traumatology and Orthopedics named after Academician N.D. Batpenov, [4] Infectious Diseases and Clinical Epidemiology, Astana Medical University

Keywords: remote ischemic preconditioning, perioperative myocardial injury, postoperative delirium, geriatric surgery, orthopedic surgery, cardioprotection, neuroprotection

https://doi.org/10.52965/001c.175660

Orthopedic Reviews

Background

Perioperative myocardial injury and postoperative delirium represent two of the most common and consequential complications in elderly patients undergoing major non-cardiac surgery. Remote ischemic preconditioning (RIPC) is a non-invasive intervention that activates endogenous protective pathways against ischemia-reperfusion injury. However, clinical evidence regarding its efficacy in high-risk geriatric orthopedic populations remains limited and controversial.

Case series

We describe three consecutive geriatric patients (ages 61-77 years) who met predefined eligibility criteria and underwent orthopedic or spine surgery under general anesthesia during April-May 2026. All patients had substantial cardiovascular comorbidity and an RCRI score of 2. A standardized RIPC protocol consisting of three cycles of 5-minute upper-limb ischemia (200-mmHg cuff inflation) followed by 5-minute reperfusion was applied immediately after induction of general anesthesia and before surgical incision. Serial postoperative monitoring included high-sensitivity cardiac troponin I (hs-cTnI), electrocardiography, and structured neurocognitive assessment using the Mini-Mental State Examination (MMSE), Confusion Assessment Method for the Intensive Care Unit (CAM-ICU), and Richmond Agitation-Sedation Scale (RASS).

Conclusion

No patient had postoperative hs-cTnI concentrations above the assay-specific upper reference limit during the monitored postoperative period. One patient experienced transient postoperative delirium on postoperative day 1, which resolved by postoperative day 2, while the remaining two patients had negative CAM-ICU assessments throughout the documented assessment period. These observations demonstrate the feasibility of applying RIPC in this clinical setting. However, given the uncontrolled three-patient case series design, they do not establish the safety, cardioprotective efficacy, or neuroprotective efficacy of RIPC.

INTRODUCTION

Cardiovascular disease remains the leading cause of mortality worldwide, accounting for approximately one-third of all deaths and representing a major public health challenge, particularly among older adults and patients with multiple comorbidities.[1] Despite substantial advances in cardiovascular prevention and treatment, perioperative cardiovascular complications continue to contribute significantly to postoperative morbidity and mortality in patients undergoing major non-cardiac surgery.[2] Myocardial injury after non-cardiac surgery (MINS), defined as an elevation of cardiac high-sensitivity cardiac troponin I (hs-cTnI) above the 99th percentile of the upper reference limit attributable to myocardial ischemia in the absence of a non-ischemic cause, is one of the most common perioperative cardiovascular complications and is independently associated with a substantially increased risk of 30-day mortality.[3]

In addition to cardiovascular events, postoperative delirium represents one of the most frequent perioperative complications in older adults. Postoperative delirium is associated with prolonged hospitalization, functional de-

cline, increased healthcare costs, reduced long-term survival, and accelerated progression to dementia. The pathophysiology of postoperative delirium is multifactorial and involves systemic inflammation, neuroinflammation, endothelial dysfunction, impaired cerebral autoregulation, disruption of the blood-brain barrier, and microcirculatory abnormalities.[4] Recent evidence has highlighted the potential involvement of neurodegeneration biomarkers (e.g., neurofilament light chain, glial fibrillary acidic protein) and blood-brain barrier dysfunction in the pathogenesis of postoperative delirium, further emphasizing the neuroinflammatory basis of this syndrome.[5,6]

Remote ischemic preconditioning (RIPC) is a non-invasive intervention consisting of brief cycles of limb ischemia and reperfusion that activate endogenous protective pathways against ischemia-reperfusion injury. The mechanisms underlying RIPC involve a complex interplay of neural and humoral signaling pathways. Neural pathways include activation of sensory afferent nerves, signal transmission via the spinal cord and autonomic ganglia, and efferent vagal signaling to target organs. Humoral mediators include adenosine, bradykinin, nitric oxide, endogenous opioids, and microRNAs transported via extracellular vesicles, which collectively modulate mitochondrial function, reduce reactive oxygen species production, and inhibit pro-inflammatory cytokine release.[7]

Several studies have demonstrated that RIPC may exert cardioprotective, anti-inflammatory, endothelial-protective, and microcirculatory effects.[8,9] Although randomized trials and meta-analyses have investigated the clinical utility of RIPC in both cardiac and non-cardiac surgery, the magnitude of its protective effect remains controversial, particularly regarding the hard clinical outcomes.[10,11]

Given the limited clinical evidence regarding the use of RIPC in older patients with elevated cardiovascular risk undergoing orthopedic and spine procedures, we present three consecutive clinical cases treated during April-May 2026. In this case series, "geriatric" was defined as age ⩾60 years, consistent with the eligibility criterion used for patient selection. These observations are intended to provide detailed clinical characterization of perioperative RIPC and to generate hypotheses for future prospective studies rather than to demonstrate treatment efficacy.

CASE PRESENTATION

STUDY DESIGN AND SETTING

This was a prospective case series conducted at the National Scientific Center of Traumatology and Orthopedics named after Academician N.D. Batpenov, a tertiary-level referral center specializing in traumatology and orthopedic surgery. Written informed consent for publication of this case series and any potentially identifiable clinical data was obtained from each patient. The study was conducted in accordance with the principles of the Declaration of Helsinki and was approved by the Local Ethics Committee of the National Scientific Center of Traumatology and Orthopedics named after Academician N.D. Batpenov (Protocol No. 3/12, dated November 5, 2025).

PATIENT SELECTION AND RECRUITMENT

The three patients were consecutively selected from patients undergoing orthopedic or trauma surgery under general anesthesia at the study center during April-May 2026. During this period, three patients underwent surgery with application of RIPC, and all three met the predefined eligibility criteria. Inclusion criteria were age ⩾60 years, written informed consent, and orthopedic or trauma surgery performed under general anesthesia. Exclusion criteria were age <60 years, unstable angina, myocardial infarction within the preceding month, planned cardiac surgery, peripheral vascular disease of the upper extremities, clinically significant cognitive impairment, participation in another randomized trial within the previous 30 days, and use of spinal anesthesia. Case 2 underwent delayed emergency surgery, whereas Cases 1 and 3 underwent elective procedures. The main perioperative events and clinical outcomes for the three patients are summarized in Figure 1.

CASE 1

A 65-year-old female patient was hospitalized for elective surgical treatment due to chronic pain and limited mobility in the right shoulder. Her medical history was notable for an initial shoulder injury in February 2020, followed by surgery in March 2020. Additional surgical interventions for nonunion (pseudarthrosis) of the humerus were performed in August 2020 and February 2021. Her background was complicated by hypertension, ischemic heart disease, chronic heart failure, coronary artery disease managed by percutaneous coronary intervention, and diabetes mellitus. Preoperative assessment classified her as ASA physical status III with a Revised Cardiac Risk Index (RCRI) score of 2, indicating increased risk of perioperative cardiac complications (Table 1).

The patient's general condition was satisfactory. Physical examination of the right shoulder region revealed postoperative scars on the lateral surface without signs of inflammation. Palpation revealed tenderness over the middle third of the right humerus. Active movement in the right shoulder joint was painless but limited: flexion 90°, extension 60°, abduction 20°. Laboratory investigations and instrumental tests upon admission were within normal limits.

Preoperative electrocardiography demonstrated sinus rhythm with signs of left ventricular hypertrophy. Echocardiography revealed a left ventricular ejection fraction of 48% with regional wall motion abnormalities consistent with prior myocardial infarction. Preoperative hs-cTnI was 8 ng/L (reference range <26 ng/L). The Mini-Mental State Examination (MMSE) score was 30/30, and the Confusion Assessment Method for the Intensive Care Unit (CAM-ICU) was negative.

The decision was made to perform removal of the fixation structures and repeat osteosynthesis with bone grafting. After obtaining written informed consent, RIPC was

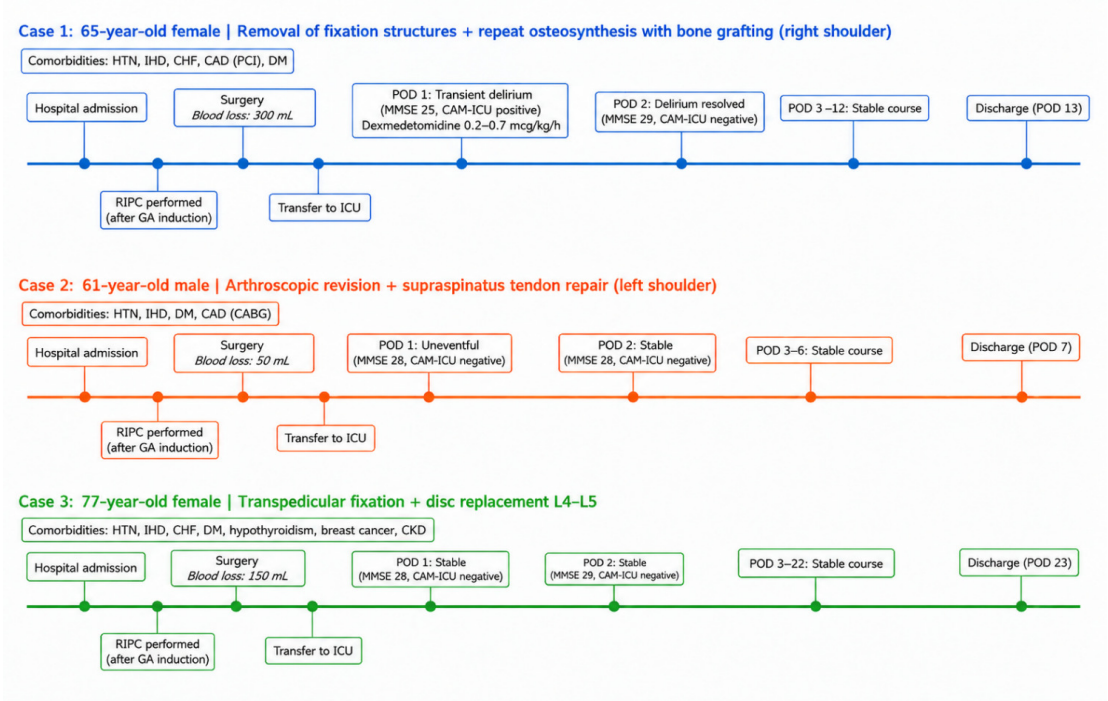

Figure 1. Perioperative timeline for three high-risk geriatric patients.

performed immediately after induction of general anesthesia and before surgical incision. A pneumatic cuff was placed on the left upper arm and inflated to 200 mmHg. The protocol consisted of three cycles of 5-minute ischemia, each followed by 5 minutes of reperfusion. Arterial occlusion during each ischemic phase was confirmed by the absence of a palpable radial pulse. General anesthesia was induced with sodium thiopental (3.5 mg/kg) and maintained with inhalational sevoflurane at a minimum alveolar concentration (MAC) of 0.8–1.0 in all three patients. No significant intraoperative hemodynamic disturbances were documented. The surgery lasted 3 hours and 20 minutes. Intraoperative blood loss was 300 mL, managed without transfusion. Prophylactic antibacterial therapy consisted of cefazolin 1,000 mg intravenously.

After surgery, the patient was transferred to the intensive care unit for postoperative care. On the first postoperative day, transient postoperative delirium was detected, confirmed by a decrease in the Mini-Mental State Examination score to 25/30 and positive delirium screening on the CAM-ICU. The clinical picture included psychomotor agitation and attention deficits consistent with diagnostic criteria for delirium. The Richmond Agitation-Sedation Scale score (RASS) was +2. Sedation with dexmedetomidine was administered as a continuous infusion at a dose of 0.2–0.7 mcg/kg/hour without a loading dose. A significant reduction in the severity of postoperative delirium occurred after 8 hours. By the second postoperative day, complete regression of delirium symptoms was observed (MMSE 29/30, CAM-ICU negative, RASS 0). No postoperative ischemic symptoms were reported, and serial ECGs showed no clinically relevant changes compared with the preoperative tracing. Hs-cTnI remained below the assay-specific upper reference limit throughout the monitored period (Figure 2). The patient was discharged on the 13th postoperative day in satisfactory condition.

CASE 2

A 61-year-old male with a medical history of hypertension, ischemic heart disease, insulin-treated diabetes mellitus, and coronary artery disease managed by coronary artery bypass grafting presented with pain and dysfunction in the left shoulder after a fall. Preoperative risk assessment classified him as ASA physical status III, with an RCRI score of 2 (Table 1). Due to the clinical need for timely restoration of shoulder joint function, he underwent delayed emergency arthroscopic revision of the left shoulder joint with supraspinatus tendon repair.

The patient's general condition on admission was relatively stable. Examination of the left shoulder joint revealed moderate soft tissue swelling. Left shoulder range of motion: active abduction 40°; passive flexion, extension, and rotation were fully preserved. Tests for anterior joint instability were negative.

Magnetic resonance imaging identified evidence of partial damage to the supraspinatus tendon. Preoperative electrocardiography demonstrated sinus rhythm. Echocardiography revealed a left ventricular ejection fraction of 52%. Preoperative hs-cTnI was 6 ng/L (reference range <26 ng/L). The MMSE score was 29/30, and the CAM-ICU was negative.

It was decided to perform urgent arthroscopic revision of the left shoulder joint with restoration of the supraspinatus tendon. After obtaining written informed consent, the same RIPC protocol and anesthetic regimen were applied as in Case 1, except that the pneumatic cuff was placed on the right upper arm, contralateral to the operative shoulder. Arterial occlusion was confirmed by the absence of a pal-

pable radial pulse during each ischemic phase. No significant intraoperative hemodynamic disturbances were documented. The duration of surgery was 55 minutes, with 50 mL estimated blood loss; no blood transfusion was required.

Postoperatively, the patient was transferred to the intensive care unit for monitoring and management. The postoperative course was uneventful, with stable hemodynamic parameters and adequate pain control. Serial ECGs remained comparable with the preoperative ECG, and no chest pain or other symptoms suggestive of myocardial ischemia were reported. Hs-cTnI remained below the assay-specific upper reference limit throughout follow-up (Figure 2). Neurocognitive assessment on postoperative days 1 and 2 demonstrated preserved cognitive function (MMSE 28/30, CAM-ICU negative, RASS 0). The patient was discharged on postoperative day 7 with satisfactory functional recovery and mobility.

CASE 3

A 77-year-old woman was admitted for elective surgical treatment due to constant pain in the lumbar spine, radiating to the lower limb, numbness in the lower limb, and weakness in the legs. She had received conservative treatment with a short-term effect. Her history included hypertension, ischemic heart disease, chronic heart failure, diabetes mellitus, hypothyroidism, cancer of the left breast, and chronic kidney disease. Preoperative assessment classified her as ASA physical status III, with an RCRI score of 2 (Table 1).

The patient's general condition was moderate due to severe pain. During examination, she ambulated independently and assumed an antalgic posture. Muscle defense was noted in the lumbar region. Palpation of the paravertebral points revealed tenderness in the projection of the L4-L5 and L5-S1 vertebrae. Lasegue's sign was positive on both sides. Numbness was present in both feet. There were no vascular disorders in the lower extremities.

Magnetic resonance imaging confirmed degenerative disc disease at L4-L5 with spinal stenosis. Renal function was relatively stable: creatinine 144 μmol/L, urea 6.27 mmol/L. Preoperative electrocardiography demonstrated sinus rhythm with left bundle branch block. Echocardiography revealed a left ventricular ejection fraction of 45%. Preoperative hs-cTnI was 10 ng/L (reference range <26 ng/L). The MMSE score was 30/30, and the CAM-ICU was negative.

The decision was made to perform transpedicular fixation and disc replacement at L4-L5. After obtaining written informed consent, the same RIPC protocol and anesthetic regimen described in Case 1 were applied, with the pneumatic cuff placed on the left upper arm. Arterial occlusion was confirmed by the absence of a palpable radial pulse during each ischemic phase. No significant intraoperative hemodynamic disturbances were documented. The surgery lasted 2 hours and 50 minutes. Intraoperative blood loss was 150 mL. Prophylactic antibacterial therapy consisted of cefazolin 2,000 mg intravenously.

After surgery, the patient was transferred to the intensive care unit for postoperative care. Postoperatively, the patient was stable with effective pain management and no complications. Serial ECGs remained comparable with the preoperative ECG. Hs-cTnI remained within normal limits throughout follow-up (Figure 2). Neurocognitive assessment on postoperative days 1 and 2 demonstrated preserved cognitive function (MMSE 28/30, CAM-ICU negative, RASS 0). The patient was discharged with satisfactory mobility on the 23rd postoperative day.

INTERVENTION

Following induction of general anesthesia and before surgical incision, RIPC was performed in all patients after written informed consent had been obtained. A pneumatic cuff was placed on the upper arm and inflated to 200 mmHg. The protocol consisted of three cycles of 5-minute ischemia, each followed by 5 minutes of reperfusion. The total duration of the RIPC protocol was 30 minutes. The intervention was performed by trained clinical staff under the direct supervision of the anesthesia team. No adverse events related to cuff inflation were observed.

OUTCOME ASSESSMENT

CARDIAC OUTCOMES

Hs-cTnI concentrations were measured preoperatively and on postoperative days 1, 2, and 3 using the Abbott ARCHITECT assay. The laboratory-reported 99th-percentile upper reference limit was 26.0 ng/L, with a single reference threshold applied to both sexes. The measured concentrations were 8, 12, 10, and 7 ng/L in Case 1; 6, 9, 7, and 5 ng/L in Case 2; and 10, 14, 11, and 8 ng/L in Case 3, respectively. All measurements remained below the upper reference limit. (Figure 2). Serial postoperative ECGs were compared with the corresponding preoperative tracings, and no clinically relevant new ischemic changes were observed. No patient reported chest pain or other symptoms suggestive of acute myocardial ischemia. MINS was defined as postoperative cardiac troponin elevation above the assay-specific 99th-percentile upper reference limit attributable to a presumed ischemic mechanism, after consideration and exclusion of alternative nonischemic causes. No patient met the criteria for MINS during the monitored postoperative period.

NEUROLOGICAL OUTCOMES

Serial clinical and psychometric assessments were performed before surgery and during the postoperative period. Postoperative delirium was assessed using the CAM-ICU, supported by clinical assessment. Cognitive status and agitation-sedation levels were evaluated using the MMSE and RASS, respectively. Assessments were performed by an anesthesiologist-intensivist and a physician-investigator in Russian, following complete discontinuation of sedation and recovery of consciousness sufficient to permit reliable evaluation. CAM-ICU, MMSE and RASS were assessed three times during the first postoperative 24 hours and once daily thereafter on postoperative day 2. The first assessment of

Table 1. Baseline Characteristics

Variable	Case 1	Case 2	Case 3
Age (years)	65	61	77
Sex	Female	Male	Female
Body mass index (kg/m^2^)	27.5	28.2	26.8
High-risk surgery	No	No	No
Comorbidities	Hypertension **Ischemic heart disease** **Chronic heart failure** Coronary artery disease (PCI) Diabetes mellitus	Hypertension **Ischemic heart disease** **Diabetes mellitus requiring insulin** Coronary artery disease (CABG)	Hypertension **Ischemic heart disease** **Chronic heart failure** Diabetes mellitus Hypothyroidism Breast cancer Chronic kidney disease
Preoperative creatinine (µmol/L)	78	85	144
Revised Cardiac Risk Index (RCRI)	2	2	2
Preoperative MMSE score	30	29	30
Preoperative hemoglobin (g/L)	128	135	118
ASA physical status	III	III	III

Abbreviations: ASA – American Society of Anesthesiologists; CABG coronary – artery bypass grafting; MMSE – Mini-Mental State Examination; PCI – percutaneous coronary intervention.

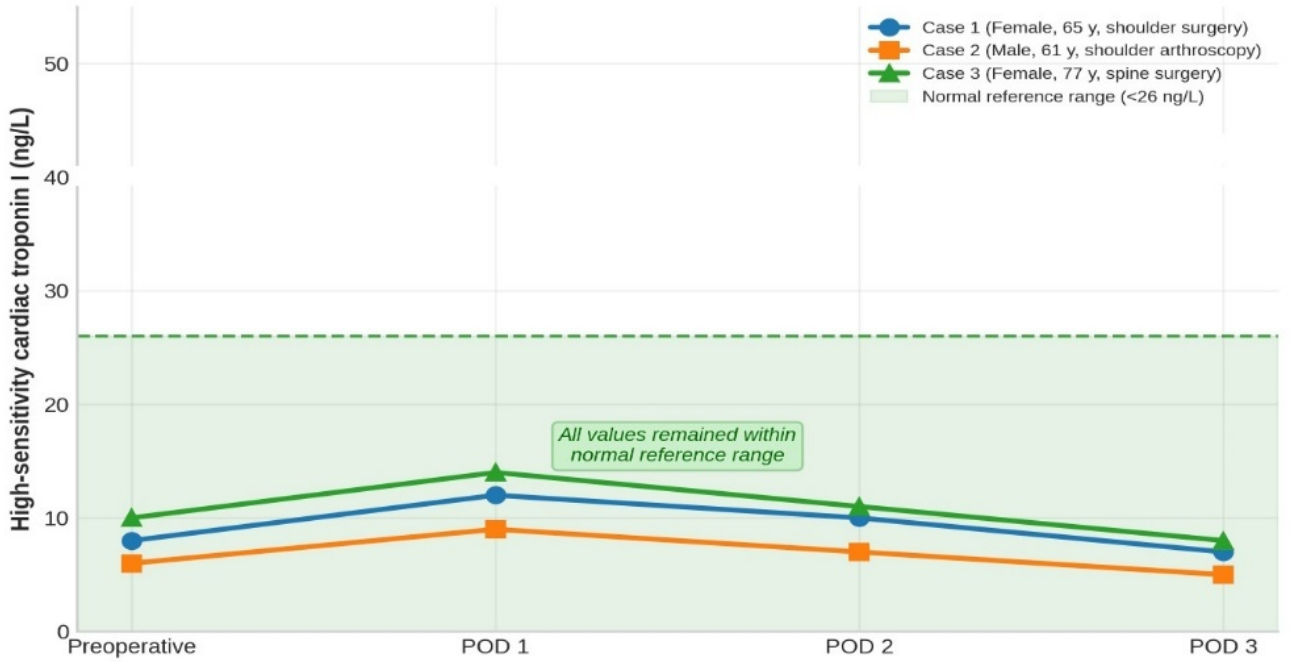

Figure 2. Dynamics of high-sensitivity cardiac troponin I (hs-cTnI) after remote ischemic preconditioning in high-risk geriatric patients.

the postoperative day 1 was used for analysis. Assessments were performed as part of routine postoperative monitoring. Case 1 had one positive CAM-ICU assessment on postoperative day 1, with RASS +2 and MMSE 25/30, followed by negative CAM-ICU and RASS 0 on postoperative day 2. Cases 2 and 3 had negative CAM-ICU assessments throughout the documented postoperative assessment period. The transient delirium episode in Case 1 resolved by postoperative day 2 (Table 2).

Table 2. Dynamics of neurocognitive status

Case	Timepoint	MMSE	CAM-ICU	RASS	Result
1	Preoperative day	30	Absent	0	Negative
	Postoperative day 1	25	Present	+2	Positive
	Postoperative day 2	29	Absent	0	Negative
2	Preoperative day	29	Absent	0	Negative
	Postoperative day 1	28	Absent	0	Negative
	Postoperative day 2	28	Absent	0	Negative
3	Preoperative day	30	Absent	0	Negative
	Postoperative day 1	28	Absent	0	Negative
	Postoperative day 2	29	Absent	0	Negative

Abbreviations: MMSE – Mini-Mental State Examination; CAM-ICU – Confusion Assessment Method for Intensive Care Unit; RASS – Richmond Agitation-Sedation Scale

DISCUSSION

This case series describes the perioperative use of RIPC in three high-risk geriatric patients undergoing orthopedic and spine surgery. All patients had substantial cardiovascular comorbidities and were therefore considered at increased risk for perioperative myocardial injury and postoperative neurocognitive complications. No postoperative hs-cTnI value exceeded the assay-specific upper reference limit, and no patient met the predefined criteria for MINS during the monitored postoperative period. One patient experienced transient postoperative delirium on postoperative day 1, which resolved by postoperative day 2. Because the case series was uncontrolled and comprised only three patients, these observations are descriptive and cannot establish cardioprotective or neuroprotective efficacy.

All measured postoperative hs-cTnI concentrations remained below the assay-specific upper reference limit through postoperative day 3. This finding is notable considering that every patient had an ASA physical status of III, a Revised Cardiac Risk Index (RCRI) = 2, and established ischemic heart disease. This observation should not be interpreted as evidence of cardioprotection because there was no control group and the sample size was very small. The absence of postoperative troponin elevation may reflect the underlying surgical and perioperative characteristics, individual patient variability, or other aspects of perioperative care. Previous meta-analyses of randomized controlled trials in non-cardiac surgery have suggested that RIPC may reduce perioperative myocardial injury and other cardiovascular complications.[12] However, the overall clinical evidence remains inconsistent. The PRINCE trial, the largest randomized controlled trial evaluating RIPC in high-risk patients undergoing non-cardiac surgery, randomized 1,213 patients to RIPC or sham preconditioning and demonstrated no significant reduction in myocardial injury (38.0% vs. 37.4%; relative risk 1.02; 95% CI 0.88-1.18; P=0.84).[10]

The variability of published results likely reflects the considerable heterogeneity among clinical studies. Differences in patient populations, surgical procedures, anesthetic techniques, timing and duration of RIPC, and outcome definitions may all influence treatment efficacy.[11]

In the present case series, one patient (Case 1) experienced transient postoperative delirium on the first postoperative day, which resolved completely within 48 hours. The remaining two patients maintained preserved cognitive function throughout documented postoperative assessment period. The transient nature of delirium in Case 1 and its rapid resolution with dexmedetomidine sedation may reflect the multifactorial etiology of this syndrome, including pain, sleep disruption, and metabolic disturbances, rather than a failure of RIPC-mediated neuroprotection. Importantly, the absence of sustained neurocognitive impairment in all three patients is encouraging given their advanced age and substantial cardiovascular comorbidity burden.

Clinical evidence regarding the neuroprotective effects of RIPC remains inconclusive. Several randomized clinical studies have reported reductions in postoperative biomarkers of cerebral injury with improvements in postoperative cognitive performance among elderly patients undergoing non-cardiac surgery.[13,14] Conversely, a recent meta-analysis of randomized controlled trials failed to demonstrate a significant reduction in postoperative delirium following cardiac surgery.[15] Collectively, these findings suggest that the effectiveness of RIPC is likely influenced by patient selection, surgical setting, perioperative management, and methodological differences among studies. Consequently, further adequately powered randomized trials using standardized RIPC protocols and comprehensive neurocognitive assessment are required.

A relevant comparison can be made with the case report by Birgin et al., who described RIPC in a 69-year-old man with Child-Pugh A cirrhosis undergoing right hepatectomy for multifocal hepatocellular carcinoma. RIPC was performed after induction using three 10-minute cycles of thigh ischemia/reperfusion at a pressure 100 mmHg above baseline systolic blood pressure. In contrast, our series included older patients undergoing orthopedic and spine surgery, with RIPC applied to the upper limb using three 5-minute cycles at 200 mmHg, and myocardial injury and

delirium assessed as the main outcomes. While both reports demonstrate the feasibility of RIPC in high-risk surgical settings, the different patient populations, surgical procedures, and RIPC protocols limit direct comparison. Moreover, the absence of a control group in both reports means that the favorable postoperative findings should be considered hypothesis-generating rather than evidence of a causal cardioprotective or neuroprotective effect.[16]

The favorable outcomes observed in our patients may differ from those reported in larger randomized trials for several reasons. First, case series are inherently subject to selection and publication bias, with successful clinical experiences more likely to be reported. Second, the very small sample size substantially increases the possibility that the observed findings occurred by chance. Third, our cohort consisted exclusively of elderly patients with significant cardiovascular comorbidity undergoing major orthopedic surgery, representing a highly selected population that may derive greater benefit from ischemic conditioning. Fourth, all patients received an identical standardized RIPC protocol consisting of three cycles of 5-minute ischemia and reperfusion applied to the upper limb immediately after induction of general anesthesia. Finally, the absence of propofol-based anesthesia and the implementation of comprehensive perioperative care – including meticulous hemodynamic management, antibiotic prophylaxis, multimodal analgesia, and early mobilization – may also have contributed to the favorable postoperative outcomes.

STRENGTHS

This case series has several important strengths. All patients represented a clinically relevant population characterized by advanced age, substantial cardiovascular comorbidity, and elevated perioperative risk, reflecting contemporary orthopedic practice. A standardized RIPC protocol was consistently applied across all cases, thereby enhancing methodological reproducibility. Serial postoperative evaluation included both hs-cTnI measurements and structured neurological assessment using validated instruments (MMSE, CAM-ICU, and RASS), enabling comprehensive evaluation of both cardiac and neurocognitive outcomes. Furthermore, the use of contemporary hs-cTnI assays increased the sensitivity for detecting even minor perioperative myocardial injury. Finally, written informed consent was obtained from all patients, and the study was conducted with approval from the institutional ethics committee.

LIMITATIONS

Several limitations should be acknowledged. First, this report includes only three patients and lacks a control group, precluding any conclusions regarding treatment efficacy. Second, the observational design does not allow causal inference between RIPC and the observed clinical outcomes. Third, the limited sample size restricts external validity and increases the likelihood of chance findings. Fourth, inflammatory biomarkers and mechanistic pathways potentially involved in RIPC-mediated organ protection were not assessed. Fifth, the absence of long-term follow-up precludes evaluation of the durability of any potential protective effects. Finally, given that large randomized clinical trials have produced conflicting results regarding the impact of RIPC on major cardiovascular and neurological outcomes, the findings of the present case series should be considered hypothesis-generating rather than confirmatory.

CONCLUSION

RIPC was completed in three older adults undergoing orthopedic and spine surgery without observed cuff-related adverse events. No measured postoperative hs-cTnI concentration exceeded the assay-specific upper reference limit through postoperative day 3. One patient developed transient postoperative delirium, which resolved by postoperative day 2. These descriptive observations document protocol delivery in this clinical setting but do not establish the safety, cardioprotective efficacy, or neuroprotective efficacy of RIPC. Further adequately powered randomized controlled trials are required to determine whether RIPC can reduce postoperative myocardial injury, delirium, and other clinically important complications in geriatric patients undergoing major non-cardiac surgery.

DATA AVAILABILITY STATEMENT

The data supporting the findings of this study are available from the corresponding author upon reasonable request. Public access is restricted to ensure patient confidentiality in accordance with the ethical standards of the institutional review board.

ETHICS STATEMENT

Written informed consent for publication of this case report and any potentially identifiable data was obtained from each patient. The study was conducted in accordance with the Declaration of Helsinki and approved by the Local Ethics Committee of the National Scientific Center of Traumatology and Orthopedics named after Academician N.D. Batpenov (Protocol No. 3/12, dated November 5, 2025).

AUTHOR CONTRIBUTIONS

Conceptualization and study design: AK, MK. Data collection: SS, ZS. Data analysis and interpretation: AK, SS. Manuscript drafting: SS. Critical revision and supervision: AK. All authors read and approved the final manuscript.

FUNDING

The author(s) declared that financial support was not received for this work and/or its publication.

CONFLICT OF INTEREST

The authors declare no conflict of interest.

ACKNOWLEDGMENTS

The authors thank the clinical and nursing staff of the National Scientific Center of Traumatology and Orthopedics named after Academician N.D. Batpenov for their assistance in patient care and data collection.

Submitted: October 14, 2026 EST. Accepted: November 07, 2026 EST. Published: November 24, 2026 EST.

REFERENCES

1. Roth GA, Mensah GA, Fuster V. The Global Burden of Cardiovascular Diseases and Risks: A Compass for Global Action. *J Am Coll Cardiol*. 2020;76(25):2980-2981. doi:10.1016/j.jacc.2020.11.021

2. Writing Committee for the VISION Study Investigators, Devereaux PJ, Biccard BM, et al. Association of Postoperative High-Sensitivity Troponin Levels With Myocardial Injury and 30-Day Mortality Among Patients Undergoing Noncardiac Surgery. *JAMA*. 2017;317(16):1642-1651. doi:10.1001/jama.2017.4360

3. Devereaux PJ, Szczeklik W. Myocardial injury after non-cardiac surgery: diagnosis and management. *Eur Heart J*. 2020;41(32):3083-3091. doi:10.1093/eurheartj/ehz301

4. Wilson JE, Mart MF, Cunningham C, et al. Delirium. *Nat Rev Dis Primers*. 2020;6(1):90. doi:10.1038/s41572-020-00223-4

5. Fong TG, Vasunilashorn SM, Ngo L, et al. Association of Plasma Neurofilament Light with Postoperative Delirium. *Ann Neurol*. 2020;88(5):984-994. doi:10.1002/ana.25889

6. Devinney MJ, Wong MK, Wright MC, et al. Role of Blood-Brain Barrier Dysfunction in Delirium following Non-cardiac Surgery in Older Adults. *Ann Neurol*. 2023;94(6):1024-1035. doi:10.1002/ana.26771

7. Donato M, Buchholz B, Rodríguez M, et al. Role of the parasympathetic nervous system in cardioprotection by remote hindlimb ischaemic preconditioning. *Exp Physiol*. 2013;98(2):425-434. doi:10.1113/expphysiol.2012.066217

8. van Zeggeren L, Visser RA, Vernooij LM, et al. The effect of remote ischaemic preconditioning on postoperative cardiac and inflammatory biomarkers in pancreatic surgery: a randomized controlled trial. *BJS Open*. 2021;5(2):zrab015. doi:10.1093/bjsopen/zrab015

9. Wahlstrøm KL, Bjerrum E, Gögenur I, Burcharth J, Ekeloef S. Effect of remote ischaemic preconditioning on mortality and morbidity after non-cardiac surgery: meta-analysis. *BJS Open*. 2021;5(2):zraa026. doi:10.1093/bjsopen/zraa026

10. Greco M, Lombardi G, Brusasco C, et al. Effect of Remote Ischemic Preconditioning on Myocardial Injury in Noncardiac Surgery: The PRINCE Randomized Clinical Trial. *Circulation*. 2025;152(17):1194-1205. doi:10.1161/CIRCULATIONAHA.125.075254

11. Ackland GL, Pinto BB. The PRINCE trial of remote ischaemic preconditioning in noncardiac surgery to reduce myocardial injury: sign o' the times. *Br J Anaesth*. 2026;136(2):475-480. doi:10.1016/j.bja.2025.11.005

12. Fresilli S, Labanca R, Turi S, et al. Remote ischaemic preconditioning and survival in noncardiac surgery: a meta-analysis of randomised trials. *Br J Anaesth*. 2025;134(5):1373-1384. doi:10.1016/j.bja.2025.02.023

13. Xu F, Liu T, Liu H, et al. Effect of remote ischemic preconditioning on perioperative neurocognitive disorder in elderly patients undergoing major surgery and associated genetic variant analysis: a randomized clinical trial. *Perioper Med (Lond)*. 2025;14(1):15. doi:10.1186/s13741-025-00497-w

14. Han M, Wu X, Li J, Han S, Rong J. Effects of Remote Ischemic Preconditioning on Postoperative Cognitive Dysfunction in Elderly Patients with Laparoscopic Cholecystectomy. *Int J Gen Med*. 2023;16:961-971. doi:10.2147/IJGM.S401902

15. Jing Y, Gao B, Li X. Influences of remote ischemic preconditioning on postoperative delirium and cognitive dysfunction in adults after cardiac surgery: a meta-analysis of randomized controlled trials. *Perioper Med (Lond)*. 2021;10(1):50. doi:10.1186/s13741-021-00216-1

16. Birgin E, Reissfelder C, Rahbari N. Remote Ischemic Preconditioning in a Cirrhotic Patient Undergoing Major Hepatectomy. *Cureus*. 2020;12(7):e9056. doi:10.7759/cureus.9056