

Therapeutic approach to combined deltoid ligament disruption with lateral malleolus fracture: Current evidence and literature review

Khalil Nasrallah, Shtarker Haim,
Bathish Einal

Galilee Medical Center, Department of
Orthopedics, Nahariya, Israel

Abstract

Ankle fractures are among the most common injuries treated by orthopaedic traumatologists. These fractures range from stable, simple injuries to complex, multi-planar unstable ones. Osseo-ligamentous structures play a paramount role in maintaining the stability of the ankle joint. The deltoid ligament is among the most important ankle static stabilizers. Rupture of this ligament along with a lateral malleolar fracture is considered by many as an unstable type of injury and usually requires surgical treatment (bi-malleolar equivalent). Left untreated, it may lead to chronic pain, loss of function and secondary arthritis. Due to lack of high-quality evidence, there are no well-defined, well-accepted criteria for the diagnosis and treatment for treating this type of injury.

Introduction

Ankle fractures are among the most common injuries treated by orthopaedic surgeons.¹ Since the ankle is a ring-like structure comprised of bony and ligamentous components, a rotational type of injury often results with the disruption of two or more structures. A deltoid ligament (DL) tear is commonly associated with a fracture of the lateral malleolus, commonly known as a “bi-malleolar equivalent” injury. Often, this occult injury goes unnoticed when using simple, static plain radiographs. By using arthroscopy, we have diagnostic evidence that DL disruption exists in 39.6% of ankle fractures.² Magnetic Resonance Imaging (MRI) in acute ankle fractures shows an incidence 58.3%.³ The most commonly described mechanism leading to this injury is supination external rotation (SER), which corresponds to AO/OTA 44B type fibula fracture.^{4,5} SER is further sub-classified into four groups, two of which are of interest to us: SER II is a stable injury without a medial lesion, while SER IV (Figure 1) is an unstable injury due to either a fracture of the medial malleolus or incompetence of the deep DL.⁶⁻⁸ As mentioned, DL dis-

ruption is often missed.^{9,10} If not treated, it may cause ankle instability, chronic pain and early traumatic arthritis of the ankle joint.^{11,12}

The correct treatment of DL disruptions associated with ankle fracture is still a matter of debate. The options can include non-operative treatment, operative fixation of the lateral injury only, and direct suture repair of the DL. The latter treatment option is still controversial. Some studies suggest early exploration and treatment of DL rupture,^{13,14} while other studies suggest conservative non-surgical treatment if anatomical reduction of the ankle mortise is achieved. Some authors advocate routine exploration of the medial side when DL disruption is suspected. This paper will review the anatomy of the DL, the diagnosis of DL disruption, and the current treatment options for this injury according to available evidence.

Anatomy and biomechanics

Three bones constitute the ankle joint: the talus, the distal tibia and the fibula. This joint is a saddle-shaped articulation supported by the medial and lateral osseo-ligamentous complexes, as well as the distal tibiofibular syndesmosis.¹⁵ The medial osseo-ligamentous complex, commonly known as the deltoid ligament (DL), consists of superficial and deep components. The superficial layer includes the tibionavicular (TNL), tibiospring (TSL), and tibio-calcaneal ligaments (TCL), which cross the ankle and subtalar joints.^{16,17} It originates from the anterior colliculus of the medial malleolus.¹⁸ The deep deltoid component originates from the larger and more distal posterior colliculus.¹⁹ It consists of two portions, the anterior tibiotalar and posterior tibiotalar ligaments.^{20,21} The superficial component stabilizes the hind foot against eversion, while the deep component stabilizes the talus against external rotation and,²² together, against valgus load. Furthermore, the deep component is considered by many as the major contributor to ankle stability.²³⁻²⁵ Ramsey *et al.* showed that even small deviations of the talus result in significantly reduced joint contact areas and emphasized the critical role of the DL in ankle stability.²⁶

Diagnosis

It is of the utmost importance to differentiate between SER II and SER IV (DL rupture without medial malleolus fracture). SER II or isolated lateral malleolus fracture is a stable injury and usually can be man-

Correspondence: Khalil Nasrallah, Galilee medical center, PO Box 21, Nahariyya 22100, Israel.
Tel. +972.49107414, mobile +972-54-7133877.
E-mail: khaliln@gmc.gov.il

Key words: deltoid ligament, trimalleolar fracture, unstable ankle fracture, bimalleolar equivalent, medial ligament complex.

Contributions: The authors contributed equally.

Conflict of interest: The authors declare no potential conflict of interest.

Funding: None.

Received for publication: 14 October 2020.
Accepted for publication: 29 November 2020.

This work is licensed under a Creative Commons Attribution NonCommercial 4.0 License (CC BY-NC 4.0).

©Copyright: the Author(s), 2021
Licensee PAGEPress, Italy
Orthopedic Reviews 2021;13:8987
doi:10.4081/or.2021.8987

aged conservatively, while SER IV is considered an unstable injury, often requiring surgical stabilization.

Clinical signs

Focal tenderness, swelling and ecchymosis over the medial malleolus suggest injury to the DL, according to some authors.²⁷ Conversely, other studies devalue the sensitivity, specificity, positive (PPV) and negative predictive value (NPV) of these physical signs in DL disruption and instability.²⁸⁻³⁰ A recent prospective study by Dabash *et al.*³¹ supports the former opinion, hence patients with medial tenderness have a significantly higher risk of having an unstable SER ankle fracture. Still, the study concluded that tenderness alone as a sole criterion for instability would lead to an unacceptable number of false positive and false negative diagnoses of instability. Another clinical sign suggested for assessing stability of the ankle fracture is the ability to bear weight immediately after the injury. A recent study has demonstrated that patients who were able bear weight are 8 times more likely to have a stable fracture.³² However, clinical assessment alone of DL rupture is essentially not acceptable for the diagnosis of DL rupture in isolated lateral malleolus fractures, thus necessitating further investigation.

Imaging

The standard ankle fracture radiographic series consists of AP, lateral and mortise views. The lateral view offers the advantage of evaluating the size of the medial malleolus fragment and assessing the anterior and posterior colliculi. This is important since involvement of the posterior colliculus suggests involvement of the deep component of DL along with its operative implications.³³ Radiographic signs, such as talar tilt and medial clear space (MCS) widening, can be assessed on AP and mortise views. The MCS is the distance between the medial wall of the talar body and the most lateral aspect of the medial malleolus. Traditionally, a normal MCS has been described as being less than 4 mm,³⁴⁻³⁶ and should be within 1 mm of the superior clear space (SCS).³⁷ Many consider an MCS of more than 4 mm as an indication for operative treatment.³⁸⁻⁴⁰ Conversely, Schuberth *et al.*⁴¹ suggested that the MCS is not a reliable indicator of deltoid ligament integrity. These authors found that, for MCS of 4 mm, the false positive rate was 53.6%. False positive rates were 26.9% and 7.7% for MCS >5 mm and >6 mm, respectively. Michelson *et al.*⁴² found that comparison of the MCS with the SCS to be more reliable for assessing DL integrity, since it serves as an internal control for radiographic magnification. This finding is consistent with other studies.⁴³

Physiologic loading and stress radiography of the ankle is thought by many to elucidate signs of instability and to be more specific than static films. This can be done either by gravity stress view (GSV) or by manual external rotation stress view (ESV). GSV confers several advantages, does not require an examiner, is less painful and gives a relatively standard amount of force (gravity).^{44,45}

The validity of stress radiographs was studied extensively on cadavers. Park *et al.*⁴⁶ dissected six fresh cadavers and sequentially disrupted the osseous-ligamentous structures depicting the SER type of injury. The authors concluded that an MCS ≥ 5 mm done in dorsiflexion was the most reliable criterion to predict deltoid incompetency with sensitivity, specificity, and positive and negative predictive values of 100%. Another cadaveric study by Ashraf *et al.*⁴⁷ also sequentially destabilized the osseous-ligamentous structures according to SER type of injury. GSVs were done in neutral and plantarflexion ankle positions. The authors concluded that the ankle position did not change the MCS in the gravity stress test.

Some clinical studies compared stress tests to various imaging modalities. A recent study by Leeuwen *et al.*⁴⁸ investigated 39 patients with a SER-type injury with MCS <6 mm in regular mortise view. All patients underwent GSV and MRI scans. The findings indicated that GSVs have a more discriminative ability for a DL tear than a regular ankle mortise view. Furthermore, Nortunen *et al.*⁴⁹ prospectively studied 61 patients with isolated lateral malleolar fractures with ankle stability being assessed using external rotation stress test and MRI. The findings showed that the vast majority of patients had partial tears, while a complete tear was rare. The authors recommended the routine use of EST rather than MRI to assess ankle stability.

Stenquist *et al.*⁵⁰ evaluated 51 isolated distal fibula fractures for medial tenderness. Seventy-nine percent of patients with a positive medial tenderness test also had an unstable fracture. The authors concluded that medial tenderness is a good screening tool for further investigating ankle stability. Schottel *et al.*⁵¹ emphasized that even absolute stress MCS measurement of greater than 5 mm is not to be used alone for diagnosing DL rupture.

A recent prospective comparative study conducted by Rosa *et al.*⁵² was made to assess the accuracy of ultrasound (US) for diagnosing DL disruption. Eighty-one patients with apparently isolated fractures of the lateral malleolus underwent GST and US. Sixty-four of the 81 were diagnosed with a DL disruption. Only eight (12.5%) cases were diagnosed with complete tears. The ultrasonography results showed 100% sensitivity, 90% specificity, 97% positive predictive value, and 100% negative predictive value in DL assessment. The authors also showed that GST with MCS >5 mm

had a complete tear of the DL.

Radiographic measurements still have several limitations due to varying degrees of magnification, ankle position, and different techniques, all of which may make measurement of the MCS difficult and challenging. Nonetheless, when there is a high index of suspicion of DL disruption, further investigation using stress radiographs and/or ultrasonography may prove to be beneficial as adjuvants for the diagnosis in suspected cases based on clinical grounds, such as tenderness, ecchymosis and mechanism of injury.

Management and outcome

There are still no generally or widely accepted guidelines on exploring the DL. Whether it should be done for all ankle fractures or only in cases in which anatomical reduction of the mortise could not be achieved due to DL interposition in the medial gutter. Some authors chose to deal with proven DL injury non-operatively, claiming that they obtained good results with low complication rates.^{53,54}

Souza *et al.*⁵⁵ studied 150 operative ankle fractures. The results were satisfactory in 90% of cases. The authors concluded that DL repair was not indicated when the lateral side was anatomically reduced and rigidly fixed. Another study came to a similar conclusion by evaluating 24 patients with lateral malleolus fractures and DL ruptures.⁵⁶ Twenty-one of these 24 underwent fracture fixation without exploration of the medial side. The results were good to excellent. This finding is consistent with the finding of Zeegers *et al.*⁵⁷ who treated 28 patients sustaining lateral malleolus frac-

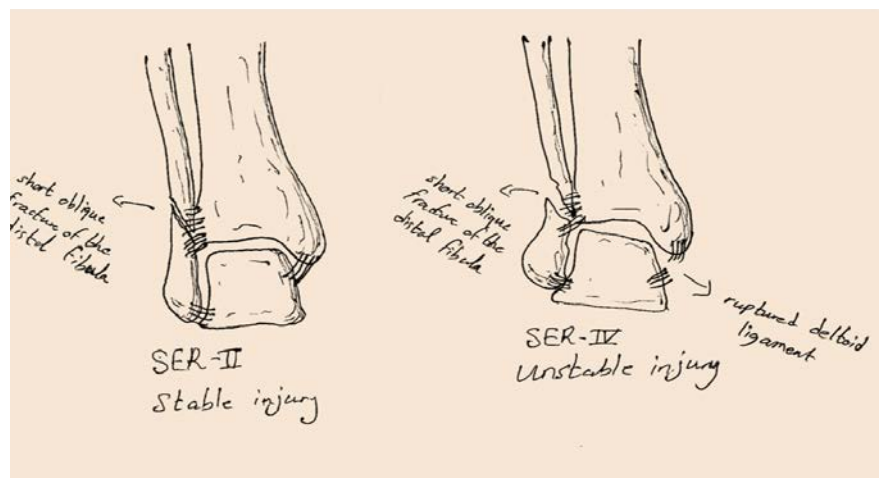


Figure 1.

tures with DL rupture, none requiring medial side exploration. The authors came to the same conclusion that, once you achieve congruent ankle mortise, there is no need to explore and repair the DL.

A recent prospective comparative study conducted by Sun *et al.*⁵⁸ evaluated 41 patients sustaining an ankle fracture with DL disruption. The patients were divided into three groups. Twelve patients were treated with superficial DL repair and fracture fixation, 16 patients were treated with deep DL augmentation in addition to fracture fixation, and 13 patients were treated conservatively. Overall, no significant statistical difference was observed in comparing the three groups. Thus, the authors did not support regular repairing or augmentation of the ruptured DL.

These studies have some limitations. The diagnosis of DL rupture was based on clinical examination and widening of the MCS on mortise view. Based on those measures alone, the diagnosis of DL rupture is not accurate as discussed earlier. Other limitations are the absence of a control group and the small sample size.

Furthermore, some studies came to the opposite conclusion and showed that unrepaired DL rupture resulted in laxity and unacceptable results.⁵⁹ Yu *et al.*⁶⁰ evaluated 106 patients diagnosed with combined lateral malleolus fracture and DL rupture. These patients underwent DL repair with fracture fixation. No medial ankle instability was noted, and operative stress radiographs were negative. Three recent comparative studies recommended that DL disruption should be repaired. Zhao *et al.*⁶¹ identified 74 ankle fractures with DL rupture, and 20 of the 74 were treated with surgical repair. Results showed that surgical repair of the DL significantly reduced the MCS and malreduction rate, especially for the AO/OTA type-C ankle fractures. Another study was conducted by Woo *et al.*⁶² evaluating 78 patients with rupture of DL with an associated ankle fracture. In this series, 41/78 underwent repair of the DL rupture. The results showed better clinical outcomes for the DL repair group and concluded that direct repair of the DL was adequate for restoring medial stability. A third comparative study was conducted prospectively by Gu *et al.*⁶³ these authors evaluated 40 patients diagnosed with ankle fracture and DL injury. Twenty of the 40 were treated with DL reconstruction along with fracture fixation. After 18 months of follow-up, the repair group showed good to excellent results, which was considerably higher than that of the control group.

A recent meta-analysis of these three comparative studies performed by Salameh

et al came to an interesting and somewhat conflicting conclusion.⁶⁴ They concluded that those who underwent DL repair along with ankle fracture fixation showed a superior early and late radiological correction of the MCS. However, there were no differences in complication rates nor functional outcome in the operated group compared to the conservative group.

Conclusions

The ultimate approach to the combined lateral malleolus fracture with deltoid ligament disruption has been studied extensively. Contrary to traditional literature, it seems that not all patients will benefit from surgical repair of the deltoid ligament. The treating surgeon should avoid misdiagnosing osseo-ligamentous injuries when encountering an isolated lateral malleolus fracture. The level of suspicion should be raised in cases of high energy injury, medial ankle tenderness or ecchymosis, supination-external rotation mechanism and enlarged MCS. There is some consensus among surgeons that DL exploration is indicated in cases of inadequate reduction of the mortise during surgery. Furthermore, surgical exploration of the medial side of the ankle is considered a minimal and safe procedure with modest comorbidity.

It is still debatable whether repairing the DL disruption is beneficial or not. There is some evidence that repairing the DL disruption improves the radiological MCS, but there is no good quality evidence that the same procedure improves the functional outcome. We recommend that any concern for deltoid ligament disruption based on clinical grounds should be further evaluated by either stress films or ultrasonography performed by an expert in musculoskeletal imaging. The therapeutic approach should be individually tailored for every patient.

When considering whether to repair the deltoid ligament or not, the surgeon must consider the fracture pattern, obstruction to reduction, soft tissue state, patient comorbidities, and level of activity.

Further high-quality studies, such as randomized control trials, are needed to create evidence-based guidelines for the treatment of DL disruption.

References

1. Brosky T, Nyland J, Nitz A, Caborn DN. The ankle ligaments: consideration of syndesmotic injury and implications for rehabilitation. *J Orthop Sports Phys*

- Ther 1995;21:197.
2. Hintermann B, Regazzoni P, Lampert C, et al. Arthroscopic findings in acute fractures of the ankle. *J Bone Joint Surg Br* 2000;82:345-51.
3. Jeong MS, Choi YS, Kim YJ, et al. Deltoid ligament in acute ankle injury: MR imaging analysis. *Skelet Radiol* 2014;43:655-63.
4. Harper M.C. The deltoid ligament. An evaluation of need for surgical repair. *Clin Orthop Relat Res* 1988:156-68.
5. Egol KA, Amirtharajah M, Amirtharage M, et al. Ankle stress test for predicting the need for surgical fixation of isolated fibular fractures. *J Bone Joint Surg Am* 2004;86-A:2393-8.
6. Bauer M, Bergström B, Hemborg A, Sandegård J. Malleolar fractures: nonoperative versus operative treatment. A controlled study. *Clin Orthop Relat Res* 1985:17-27.
7. McConnell T, Creevy W, Tornetta P. Stress examination of supination external rotation-type fibular fractures. *J Bone Joint Surg Am* 2004;86A:2171-8.
8. Kwon JY, Cronin P, Velasco B, Chiodo C. Evaluation and significance of mortise instability in supination external rotation fibula fractures: a review article. *Foot Ankle Int* 2018;39:865-73.
9. Beumer A, van Hemert WLW, Niesing R, et al. Radiographic measurement of the distal tibiofibular syndesmosis has limited use. *Clin Orthop Relat Res* 2004:227-34.
10. Nortunen S, Lepojärvi S, Savola O, et al. Stability assessment of the ankle mortise in supination-external rotation-type ankle fractures: lack of additional diagnostic value of MRI. *J Bone Joint Surg Am* 2014;96:1855-62.
11. Kusnezov NA, Eisenstein ED, Diab N, et al. Medial Malleolar fractures and associated deltoid ligament disruptions: current management controversies. *Orthopedics* 2017;40:e216-22.
12. Yu GR, Zhang MZ, Aiyer A, et al. Repair of the acute deltoid ligament complex rupture associated with ankle fractures: a multicenter clinical study. *J Foot Ankle Surg* 2015;54:198-202.
13. Baird RA, Jackson ST. Fractures of the distal part of the fibula with associated disruption of the deltoid ligament. Treatment without repair of the deltoid ligament. *J Bone Joint Surg Am* 1987;69:1346-52.
14. Harper MC. The deltoid ligament. An evaluation of need for surgical repair. *Clin Orthop Relat Res* 1988:156-68.
15. Michelson JD. Ankle fractures resulting from rotational injuries. *J Am Acad Orthop Surg* 2003;11:403-12.

16. Milner CE, Soames RW. The medial collateral ligaments of the human ankle joint: anatomical variations. *Foot Ankle Int* 1998;19:289.
17. Hintermann B, Valderrabano V, Boss A, et al. Medial ankle instability. *Am J Sports Med* 2004;32:183.
18. Tornetta P III. Competence of the deltoid ligament in bimalleolar ankle fractures after medial malleolar fixation. *J Bone Joint Surg Am* 2000;82:843-848.
19. Tornetta P III. Competence of the deltoid ligament in bimalleolar ankle fractures after medial malleolar fixation. *J Bone Joint Surg Am* 2000;82:843-848.
20. Milner CE, Soames RW. The medial collateral ligaments of the human ankle joint: anatomical variations. *Foot Ankle Int* 1998;19:289.
21. Hintermann B, Valderrabano V, Boss A, et al. Medial ankle instability. *Am J Sports Med* 2004;32:183.
22. Davidovitch RI, Egol KA. The medial malleolus osteoligamentous complex and its role in ankle fractures. *Bull NYU Hosp Jt Dis* 2009;67:318-24.
23. Michelsen JD, Ahn UM, Helgemo SL. Motion of the ankle in a simulated supination-external rotation fracture model. *J Bone Joint Surg Am* 1996;78:1024-31.
24. Jeong MS, Choi YS, Kim YJ, et al. Deltoid ligament in acute ankle injury: MR imaging analysis. *Skeletal Radiol* 2014;43:655-63.
25. Pankovich AM. Acute indirect ankle injuries in the adult. 1981. *J Orthop Trauma* 2002;16:58-68
26. Ramsey PL, Hamilton W. Changes in tibiotalar area of contact caused by lateral talar shift. *J Bone Joint Surg Am* 1976;58:356-7.
27. Lötscher P, Lang TH, Zwicky L, et al. Osteoligamentous injuries of the medial ankle joint. *Eur J Trauma Soc* 2015;41:615-21.
28. Egol KA, Amirtharajah M, Amirtharage M, et al. Ankle stress test for predicting the need for surgical fixation of isolated fibular fractures. *J Bone Joint Surg Am* 2004;86-A:2393-8
29. McConnell T, Creevy W, Tornetta P. Stress examination of supination external rotation-type fibular fractures. *J Bone Joint Surg Am* 2004;86-A:2171-8
30. Lauge-Hansen N. Ligamentous ankle fractures; diagnosis and treatment. *Acta Chir Scand* 1949;97:544-50
31. Dabash S, Elabd A, Potter E, et al. Adding deltoid ligament repair in ankle fracture treatment: Is it necessary? A systematic review. *Foot Ankle Surg* 2019;25:714-20.
32. Chien B, Hofmann K, Ghorbanhoseini M, et al. Relationship of self-reported ability to weight-bear immediately after injury as predictor of stability for ankle fractures. *Foot Ankle Int* 2016;37:983-8.
33. Tornetta P III. Competence of the deltoid ligament in bimalleolar ankle fractures after medial malleolar fixation. *J Bone Joint Surg Am* 2000; 82:843-8.
34. Cedell CA. Supination-external rotation injuries of the ankle: a clinical and roentgenological study with special reference to the operative treatment. *Acta Orthop Scand* 1967;38:1-148.
35. Harager K, Hviid K, Jensen CM, Schantz K. Successful immediate weight-bearing of internal fixated ankle fractures in a general population. *J Orthop Sci* 2000;5:552-4.
36. McConnell T, Creevy W, Tornetta P III. Stress examination of supination external rotation-type fibular fractures. *J Bone Joint Surg Am*. 2004;86-A:2171-8.
37. McConnell T, Creevy W, Tornetta P III. Stress examination of supination external rotation-type fibular fractures. *J Bone Joint Surg Am*. 2004;86-A:2171-8.
38. Phillips WA, Schwartz HS, Keller CS, et al. A prospective, randomized study of the management of severe ankle fractures. *J Bone Joint Surg Am* 1985;67:67-78
39. Pankovich AM, Shivaram MS. Anatomical basis of variability in injuries of the medial malleolus and the deltoid ligament. II. Clinical studies. *Acta Orthop Scand* 1979;50:225-36
40. Michelson JD, Varner KE, Checcone M. Diagnosing deltoid injury in ankle fractures: the gravity stress view. *Clin Orthop Relat Res* 2001:178-82.
41. Schubert JM, Collman DR, Rush SM, Ford LA. Deltoid ligament integrity in lateral malleolar fractures: a comparative analysis of arthroscopic and radiographic assessments. *J Foot Ankle Surg* 2004;43:20-9.
42. Michelson JD. Ankle fractures resulting from rotational injuries. *J Am Acad Orthop Surg* 2003;11:403-12.
43. DeAngelis JP, Anderson R, DeAngelis NA. Understanding the superior clear space in the adult ankle. *Foot Ankle Int* 2007;28:490-3
44. Jastifer JR, Jaykel M. Results of the gravity stress examination in the normal patient population. *Foot Ankle Spec* 2017;10:398-401.
45. van den Bekerom MPJ, ELAR Mutsaerts, van Dijk CN. Evaluation of the integrity of the deltoid ligament in supination external rotation ankle fractures: a systematic review of the literature. *Arch Orthop Trauma Surg* 2009;129:227-35.
46. Park SS, Kubiak EN, Egol KA, et al. Stress radiographs after ankle fracture: the effect of ankle position and deltoid ligament status on medial clear space measurements. *J Orthop Trauma* 2006;20:1-18.
47. Ashraf A, Murphree J, Wait E, et al. Gravity Stress Radiographs and the Effect of Ankle Position on Deltoid Ligament Integrity and Medial Clear Space Measurements. *J Orthop Trauma* 2015;31:270-4.
48. van Leeuwen C, Haak T, Kop M, et al. The additional value of gravity stress radiographs in predicting deep deltoid ligament integrity in supination external rotation ankle fractures. *Eur J Trauma Emerg Surg* 2019;45:727-75.
49. Nortunen S, Lepojarvi S, Savola O, et al. Stability assessment of the ankle mortise in supination-external rotation-type ankle fractures: Lack of additional diagnostic value of MRI. *J Bone Joint Surg Am* 2014; 96:1855-62.
50. Stenquist DS, Miller C, Velasco B et al. Medial tenderness revisited: Is medial ankle tenderness predictive of instability in isolated lateral malleolus fractures? *Injury* 2020. <https://doi.org/10.1016/j.injury.2020.03.029>
51. Schottel P, Fabricant P, Berkes M, et al. Manual Stress Ankle Radiography Has Poor Ability to Predict Deep Deltoid Ligament Integrity in a Supination External Rotation Fracture Cohort. *J Am Coll Foot Ankle Surg* 2014;54. 10.1053/j.jfas.2014.07.007.
52. Rosa I, Rodeia J, Fernandes PX, et al. Ultrasonographic Assessment of Deltoid Ligament Integrity in Ankle Fractures. *Foot Ankle Int* 2020;41:147-53.
53. Harper MC. Deltoid ligament: an anatomical evaluation of function. *Foot Ankle* 1987;8:19.
54. Baird RA, Jackson ST. Fractures of the distal part of the fibula with associated disruption of the deltoid ligament. Treatment without repair of the deltoid ligament. *J Bone Joint Surg Am* 1987;69:1346
55. De Souza L, Gustilo RB, Meyer TJ. Results of operative treatment of displaced external rotation-abduction fractures of the ankle. *JBJS* 1985;67:1066.
56. Baird RA, Jackson ST. Fractures of the distal part of the fibula with associated disruption of the deltoid ligament. Treatment without repair of the deltoid

- ligament. *J Bone Joint Surg Am* 1987;69:1346-52.
57. Zeegers AV, van der Werken C. Rupture of the deltoid ligament in ankle fractures: should it be repaired? *Injury* 1989;20:39.
58. Sun X, Li T, Sun Z, et al. (). Does routinely repairing deltoid ligament injuries in type B ankle joint fractures influence long term outcomes? *Injury* 2018;49:2312-7.
59. Johnson D, Hill J. Fracture-dislocation of the ankle with rupture of the deltoid ligament. *Injury* 1988;19:59.
60. Yu GR, Zhang MZ, Aiyer A, et al. Repair of the acute deltoid ligament complex rupture associated with ankle fractures: A multicenter clinical study. *J Foot Ankle Surg* 2015;54:198-202.
61. Zhao HM, Lu J, Zhang F et al. Surgical treatment of ankle fracture with or without deltoid ligament repair: a comparative study. *BMC Musculoskelet Disord* 2017;18:543.
62. Woo SH, Bae SY, Chung HJ. Short-term results of a ruptured deltoid ligament repair during an acute ankle fracture fixation. *Foot Ankl Int* 2018;39:35-45.
63. Gu G, Yu J, Huo Y, et al. Efficacy of deltoid ligament reconstruction on the curative effect, complication and long-term prognosis in ankle fracture-dislocation with deltoid ligament injury. 2017;10. www.ijcem.com.
64. Salameh M, Alhammoud A, Alkhatib N, et al. Outcome of primary deltoid ligament repair in acute ankle fractures: a meta-analysis of comparative studies. *Int Orthop* 2020;44:341-7.

Non-commercial use only