

Traumatic infra-renal aortic dissection after a high-energy trauma: a case report of a primary missed diagnosis

Holger Godry,¹ Guido Rölleke,¹
Achim Mumme,² Thomas A. Schildhauer,¹
Martin Gothner¹

¹Department of General and Trauma Surgery, BG-University Hospital Bergmannsheil, Ruhr-University Bochum;

²Department of Vascular Surgery, St. Josef Hospital, Ruhr-University Bochum, Germany

Abstract

A traumatic infra-renal aortic dissection is a rare but life-threatening injury that follows deceleration injuries. The mechanism of blunt abdominal aortic injury involves both direct and indirect forces. The successful management of patients with traumatic injuries depends on a prompt suspicion of the injury and early diagnosis and therapy. Missed injuries in trauma patients are well-described phenomena and implementation of the ATLS® trauma schedule led to a decrease in the number of missed injuries, but trauma computed tomography (CT) scans in injured patients are still not standard. We report on a 54-year old Caucasian female patient who was involved in a car accident. The fellow passenger of the car was seriously injured. The patient had been previously treated at two different hospitals, and a dislocated acetabular fracture had been diagnosed. Because of this injury, the patient was transferred to our institution, a level 1 trauma-center where, according to the nature of the accident as a high-energy trauma, a complete polytrauma management was performed at the time of admission. During the body check, a moderate tension of the lower parts of the abdomen was detected. During the CT scan, an aneurysm of the infra-renal aorta with a dissection from the height of the second lumbar vertebral body to the iliac artery was observed. The patient required an operation on the day of admission. After 19 days post-trauma care the patient was able to leave our hospital in good general condition. Therefore, missed injuries in multiple injury patients could be fatal, and it is essential that the orthopedic surgeon leaves room for suspicion of injuries based on the nature of the trauma. Traumatic injuries of the abdominal aorta are rare. According to the ATLS® trauma schedule, all of the patients who have experienced high-energy trauma and associated fractures should undergo routine screening using a

trauma CT scan with contrast agents to detect potential life-threatening injuries. In case of abdominal trauma, an aortic dissection, which can easily be overlooked, has to be considered.

Introduction

Acute traumatic aortic injuries are rare.¹ They are normally caused by direct or indirect forces to the abdomen induced by high-energy trauma often associated with rapid deceleration.¹ Approximately 90% of acute traumatic lesions are caused by non-penetrating car accidents.² A non-penetrating blunt trauma to the abdomen may cause severe intra-abdominal injuries, an occlusion of the aorta, a dissection, a rupture or transection, an aortic aneurysm, or an aorto-caval fistula.³ Disruption of the intima, subintimal hematoma and thrombosis are sometimes observed in peripheral arteries following blunt trauma.⁴ Most acute traumatic injuries of the abdominal aorta are usually fatal before medical assistance can be given. If the diagnosis can be made immediately, surgical treatment is indicated. More rarely a patient can develop a traumatic aneurysm of the abdominal aorta.³

Because of the rare and uncommon occurrence of an acute infra-renal aortic dissection following a high-energy trauma, it is essential for the orthopedic trauma surgeon to understand the nature of the injury. Implementation of the ATLS® trauma schedule leads to a decrease in the number of missed injuries and patients can be offered adequate treatment.⁵

We present a rare and life-threatening infra-renal aortic dissection after blunt abdominal trauma which was initially not detected and highlights the necessity of understanding the nature of the trauma, its subsequent injuries, and the necessity for a computed tomography (CT) scan with intravenous (i.v.) contrast enhancement in patients with high-energy impacts, especially to the abdomen and pelvis.

Case Report

We report a 54-year old Caucasian female patient who was involved in a car accident. She was the driver of the car, and was hit by another car on the driver's side. The fellow passenger of the car was seriously injured and was treated in hospital for traumatic brain injury. Both of the passengers were wearing their seatbelts correctly, and the female patient did not lose consciousness.

At the first hospital, where the female patient underwent pelvic X-ray, an acetabular fracture on the left side was detected. The patient was then transported to the second

Correspondence: Holger Godry, Department of General and Trauma Surgery, BG-University Hospital Bergmannsheil, Ruhr-University Bochum, Bürkle de-la-Camp Platz 1, 44789 Bochum, Germany. Tel. +49.234.3020. E-mail: holger.godry@bergmannsheil.de

Key words: traumatic aortic dissection, missed injury, high-energy trauma, computed tomography scan.

Contributions: HG collected the data and was a major contributor to the manuscript; GR analyzed the data on the aortic injuries; AM contributed to the operative treatment of the acute aortic injuries; TAS contributed to the treatment of multiple injured patients; MG analyzed the patient data.

Conflict of interests: the authors declare no potential conflict of interests.

Received for publication: 15 August 2013.

Revision received: 18 November 2013.

Accepted for publication: 21 November 2013.

This work is licensed under a Creative Commons Attribution NonCommercial 3.0 License (CC BY-NC 3.0).

©Copyright H. Godry et al., 2014

Licensee PAGEPress, Italy

Orthopedic Reviews 2014; 6:5031

doi:10.4081/or.2014.5031

hospital, where a CT scan of the pelvis was performed. This revealed a multiple-fragment fracture of the left acetabulum. The patient was later given a tetanus vaccination and a trans-urethral catheter was put in place. At this time, urine did not show any signs of macroscopic hematuria.

Later, following communication via telephone, the patient was brought to our institution, a level 1 trauma-center, by helicopter. Because of the nature of the accident, with a high-energy trauma, complete polytrauma management was performed. During the body check, under pain in the left part of the pelvis, a moderate tension of the lower parts of the abdomen was observed. The ultrasound did not reveal any free abdominal fluid. Blood count showed normal values. In addition to the multiple-fragment fracture of the left acetabulum, the CT scan revealed an aneurysm of the infra-renal aorta with a dissection from the height of the second lumbar vertebral body to the iliac artery (Figures 1 and 2).

Because of the aneurysm, the patient required operative vascular surgical intervention on the day of admission. During this operation, a vascular substitute of the aorta with a 14/7 mm Dacron-Y-prosthesis was used to reconnect the superior mesenteric artery.

Nine days postoperatively, the open reduc-

tion and internal fixation of the acetabular fracture was performed without any incidence.

Nineteen days post trauma, the patient was discharged from the hospital in good general condition. She did not show any signs of vascular deficits of the lower limbs or in the abdominal organs.

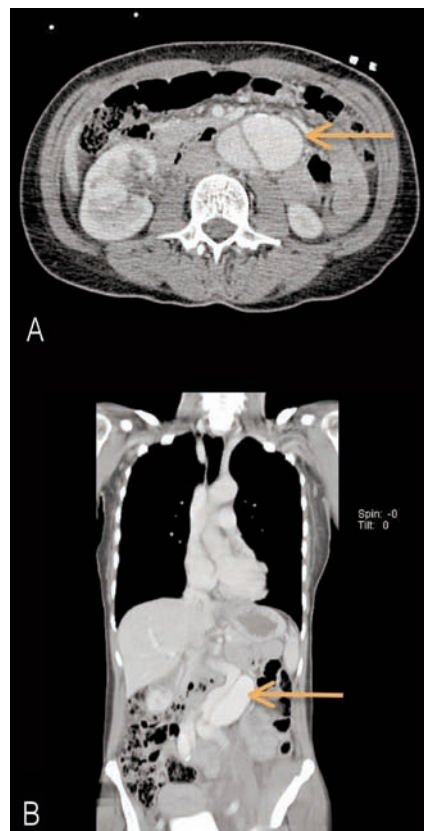


Figure 1. Computed tomography scan of the abdomen shows the dissection of the infrarenal abdominal aorta. A) Axillary and B) coronal view.

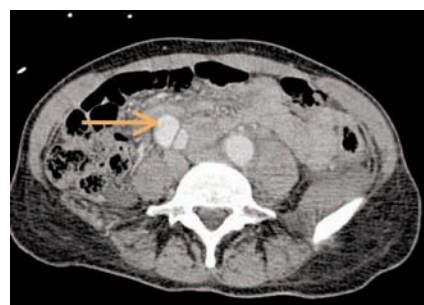

Figure 2. Axillary computed tomography scan shows the expansion of the dissection to the iliac artery.

Discussion

Acute traumatic dissection of the infra-renal abdominal aorta is a rare injury and has not been well described in the current literature. It is likely that most patients who experience traumatic aortic dissection die at the scene of the accident before medical assistance can be given. The injury to the abdominal aorta is due to either a direct or indirect abdominal compression following a sudden deceleration caused by the transmission of forces applied to the body surface.^{6,7} In both direct and indirect trauma, an intima tear can occur, allowing circulating blood to penetrate into the vessel wall to various degrees.⁶ When these injuries are suspected, radiographic evaluation must include a CT scan or magnetic resonance imaging with contrast agents for an early diagnosis. In fact, an early diagnosis must be made in order to determine the clinical course, the prognosis and the method of treatment.⁶ The examination of choice in patients with an acute traumatic dissection of the aorta seems to be aortography.⁶ In traumatic non-penetrating injuries of the abdomen, most dissections show a transverse disruption; this trend was observed by Parmley in a report of 296 cases of aortic injury.⁸ Compared to the abdominal aorta, traumatic injuries of the thoracic aorta are well-described and most likely 90% of all these injuries are caused by non-penetrating blunt trauma, such as car accidents.² A traumatic abdominal aortic aneurysm has been reported on two occasions, and each resulted from a longitudinal disruption of the aorta.⁹

Open surgery using prosthesis or a percutaneous intervention are potential options for treatment of aortic injuries.⁶

Radiographic evaluation and assessment of polytrauma patients with suspected aortic dissection must be based on an understanding of the capabilities of the various imaging techniques. Diagnostic procedures involving either the thoracic or abdominal aorta play a key role in determining the clinical course.⁶

The temporary management of initially stable patients involves using pharmacological agents to reduce the systolic blood pressure and its cardiac shear forces.¹ However, the treatment of choice is an immediate vascular surgical reconstruction.¹⁰

The current literature describes only a few cases of traumatic abdominal aortic dissection. Eimany *et al.* presented the case of a 65-year old man who was admitted to hospital after a car accident. In contrast to the present case, this patient presented completely ischemic lower extremities. The CT scan showed a traumatic aortic dissection at the

level of the inferior mesenteric artery and an aorto-femoral bypass was performed.¹¹

Ngu *et al.* discussed the case of a 37-year old woman who received a severe abdominal impact while using a surfboard. In this patient, the dissected intima was forced against the posterior wall of the aorta, occluding the lumen and causing a thrombosis.¹² In 1969, Hewitt *et al.* discussed the case of a 65-year old man who was admitted to hospital with an aortic dissection after a car accident; the patient was treated using a Dacron aorto-femoral bypass.⁴

In the current case, the aortic dissection of the patient was not recognized during the treatment in the first two hospitals. This might be due to the acetabular fracture, which was detected in both clinics. The symptoms of this injury might possibly have covered the signs associated with the aortic injury. As described above, traumatic dissection of the aorta is rare, but does have to be considered in patients with high-energy injuries of the abdomen or the pelvis with specific symptoms (*e.g.* pulse abnormalities in the lower extremities or abdominal pain). Therefore, when there is the suspicion of this kind of injury, a radiological survey with contrast agents must be carried out. In general, it is essential for any trauma unit in which patients are treated after high-energy accidents to perform standardized trauma CT scans with contrast agents to reduce the number of missed injuries.

Conclusions

The mechanism of abdominal aortic injury mostly consists of blunt injuries due to compression. Early treatment and diagnosis is essential to optimize patient outcome.

The primary treatment and the response of the orthopedic trauma surgeon following a high-energy trauma are essential factors that determine the clinical course of the patient. In the case of high-energy trauma, and even more so in those cases in which the fellow passerenger has sustained multiple injuries, a complete clinical examination, including sonography of the abdomen according to the FAST-concept and a complete trauma CT scan with contrast agents, is essential to reduce the number of missed injuries that could be fatal for the patient. Even if the patient was first seen at another hospital, and fractures are diagnosed by the orthopedic surgeon on admission, other combinations of life-threatening injuries should always be considered. In case of abdominal and pelvic trauma, abdominal aortic dissection, which can easily be overlooked, has to be considered as differential diagnosis.

References

1. Walker WA, Pate JW. Medical management of acute traumatic rupture of the aorta. *Ann Thorac Surg* 1990;50:965-7.
2. Fleming AW, Green DC. Traumatic aneurysms of the thoracic aorta. Report of 43 patients. *Ann Thorac Surg* 1974;18:91-101.
3. Sethi GK, Scott SM, Takaro T. False aneurysm of the abdominal aorta due to blunt trauma. *Ann Surg* 1975;182:33-6.
4. Hewitt RL, Grablowsky OM. Acute traumatic dissecting aneurysm of the abdominal aorta. *Ann Surg* 1970;171:160-2.
5. American College of Surgeons. Advanced trauma life support for doctors. 2008. ATLS Student Course Manual. Eight Edition.
6. Peterson AH, Williams DM, Rodriguez JL, Francis IR. Percutaneous treatment of a traumatic aortic dissection by balloon fenestration and stent placement. *AJR Am J Roentgenol* 1995;164:1274-6.
7. Macura KJ, Corl FM, Fishman EK, Bluemke DA. Pathogenesis in acute aortic syndromes: aortic dissection, intramural hematoma, and penetrating atherosclerotic aortic ulcer. *AJR Am J Roentgenol* 2003;181:309-16.
8. Parmley LF, Manion WC, Mattingly TW. Nonpenetrating traumatic injury of the heart. *Circulation* 1958;18:371-96.
9. Griffen WO Jr, Belin RP, Walder AI. Traumatic aneurysm of the abdominal aorta. *Surgery* 1966;60:813-6.
10. White A, Broder J. Acute aortic emergencies-part 1: aortic aneurysms. *Adv Emerg Nurs J* 2012;34:216-29.
11. Eimany A, Roberts AK. Acute infrarenal aortic dissection, bilateral ischaemia of lower limbs: a rare presentation. *Aust N Z J Surg* 1998;68:615-7.
12. Anomah NV, Konstam PG. Traumatic dissecting aneurysm of the abdominal aorta. *Br J Surg* 1965;52:981-2.

non commercial use only