

# Using a reconstruction locking compression plate as external fixator in infected open clavicle fracture

Norachart Sirisreetreerux,<sup>1</sup>  
Paphon Sa-ngasoongsong,<sup>1</sup>  
Pongsthor Chanplakorn,<sup>1</sup>  
Noratop Kulachote,<sup>1</sup>  
Sukij Laohajaroensombat,<sup>1</sup>  
Chanyut Suphachetwong,<sup>1</sup>  
Vajara Phiphobmongkol,<sup>2</sup>  
Wiwat Wajanavisit<sup>1</sup>

<sup>1</sup>Faculty of Medicine, Ramathibodi Hospital, Mahidol University;

<sup>2</sup>Department of Orthopaedic Surgery, Bhumibol Adulyadej Hospital, Royal Thai Air Force, Thailand

## Abstract

Open clavicle fracture is an uncommon injury mostly caused by severe direct trauma. It is often associated with multiple organ injuries. Generally, surgical intervention with debridement and fracture repair is always indicated in order to prevent infection, non-union, and malalignment. In situations of bony exposure and significant contamination concomitant with severe soft tissue damage, the external fixation is the treatment of choice because of the possibility it offers of providing stable fixation with minimal local tissue damage resulting in excellent union rates and better soft tissue outcome. Nevertheless, traditional external fixation encountered some potential problems as its bulkiness and sharp edges caused discomfort to the patient. In this study, we present an interesting case of a polytraumatized patient with a gunshot injury with complex open clavicle fracture that was successfully treated with external fixation using reconstruction with a locking compression plate as definitive treatment.

## Case Report

A 20-year old male involved in a penetrating ballistic trauma from close-range shotgun wounds was examined for multiple organ injuries. He had initially been sent to a nearby hospital for emergency treatment. The primary survey revealed severe respiratory distress and shock with multiple contaminated gunshot wounds on his upper back and right upper chest. Massive pneumothorax had been diagnosed and had been immediately treated

with endotracheal intubation, bilateral intercostal drainage (ICD) insertion, and rapid resuscitation with fluid and blood transfusions. Unfortunately, because of severe injuries and massive blood loss, he had had five episodes of cardiac arrest and required multiple cardiopulmonary resuscitations and emergency right thoracotomy with partial lobectomy of the right lung. After his vital signs had been stabilized, a secondary examination revealed that he had open right clavicle fracture (Gustilo and Anderson grade III), open right 2<sup>nd</sup> rib fracture, T2 vertebral fracture with complete spinal cord injury, and suspected tracheal rupture. Due to the patient's *in extremis* status, all open wounds were treated with bedside irrigation and removal of all visible pellets, daily dressing and intravenous antibiotics. He was referred to our hospital on Day 6 after injury for definitive management.

On admission to our hospital, the patient was in a stable condition and the ICD drainage was inactive. However, he was in a condition of respiratory distress requiring a mechanical ventilator for respiratory support and had complete spinal cord injury below T2 level. Our examination revealed low-grade fever and positive sign of infection of his gunshot wounds with turbid serosanguinous discharge, especially the right clavicle wound. X-rays showed multiple metallic fragments in the right clavicular area with comminuted clavicle fracture, and multiple pellets on coracoid, right upper lung, and upper thoracic spine (Figure 1). The tracheal rupture was not found by fiber optic bronchoscope; however, tracheostomy was performed due to expectation of a prolonged intubation period. The neurosurgeon consultant decided to treat the spinal cord injury non-operatively because of non-reconstructible spinal cord damage and because there was no further need for pellets to be removed.

Pre-operative planning for open clavicle fracture was discussed. The initial plan was serial debridement with delayed open reduction and internal fixation (ORIF) with plate after the wound had improved and once there was no sign of infection. On the first debridement, the wound was explored and showed severe soft tissue damage and significant contamination from multiple fragments of small metallic material with comminuted midshaft clavicle fracture. The tissue culture was sent for biopsy after complete debridement and an arm sling was used to immobilize the clavicle fracture. Unfortunately, the wound still had persistent turbid serosanguinous drainage with no improvement in the severe soft tissue inflammation, and the culture was positive for multidrug resistant (MDR) *Acinetobacter baumannii*. Moreover, the patient was also unable to tolerate rolling into a right semi-decubitus position *as per*

Correspondence: Paphon Sa-ngasoongsong, Department of Orthopaedics, Faculty of Medicine, Ramathibodi Hospital, Mahidol University, 270, Rama VI Road, Ratchathewi, Bangkok, 10400 Thailand.  
Tel. +66.22011589 - Fax: +66.22011599  
E-mail: chan3s@hotmail.com  
paphonortho@gmail.com

Key words: open clavicle fracture, LCP external fixation, damage control surgery.

Acknowledgments: the authors thank the Department of Orthopaedics, Faculty of Medicine, Ramathibodi Hospital, Mahidol University for all of their kind support and their permission to carry out this study.

Contributions: NS and PS performed surgery, reviewed the literature, and prepared the manuscript. PC helped in manuscript preparation. NK, SL, CS, VP and WW provided intellectual input.

Conflict of interests: the authors declare no potential conflict of interests.

Received for publication: 6 November 2012.

Revision received: 8 March 2013.

Accepted for publication: 26 March 2013.

This work is licensed under a Creative Commons Attribution NonCommercial 3.0 License (CC BY-NC 3.0).

©Copyright N. Sirisreetreerux et al., 2013  
Licensee PAGEPress, Italy  
Orthopedic Reviews 2013; 5:e11  
doi:10.4081/or.2013.e11

precautionary protocol against bedsores because of severe pain at the right clavicle. Therefore, during a second surgical intervention, surgical planning was debridement and external fixation with a reconstruction locking compression plate (LCP) in order to fix the unstable fracture, allow the patient ambulation with less pain, and provide better wound care (Figure 2). In this case, we decided to use reconstruction LCP as external fixator instead of using a conventional external fixation system or conventional LCP plate for two reasons. First, the LCP external fixation was a low-profile construct without sharp edges compared to a conventional external fixator; therefore, an LCP external fixator would cause less problems of skin irritation, such as wound abrasion, and it made the patient more comfortable while performing daily activities or the rehabilitation program. Second, when compared with conventional LCP, reconstruction LCP can bend and contour along the clavicular surface in order to adjust the direction of the locking screw to obtain an appropriate bone purchase and create good fracture stability after fixation.

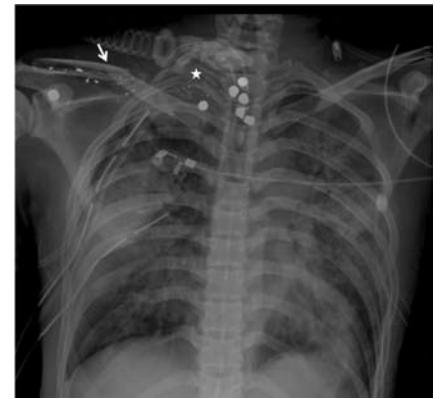## Surgical technique for external fixation of clavicle with reconstruction locking compression plate

After general anesthesia, the patient was placed in a supine position with bolster support under the right scapula on the radiolucent table in order to extend the shoulder and help fracture reduction. Debridement was carefully performed to prevent further soft tissue injury. The fracture was then reduced by shoulder extension and direct manipulation. In this case, because of unacceptable alignment, 2.0 mm Kirschner wires were inserted into both medial and lateral clavicle fragments and used as joysticks for reduction and maintaining the alignment while LCP external fixation was applied. The decision as to screw position, screw direction, and plate length was determined before screw insertion. Generally, reconstruction LCP can be contoured and placed in various positions such as superior, anterior, antero-inferior plane, because of its low profile design and angular stability, but careful attention is needed while drilling and inserting the screw to avoid major neurovascular injury under the clavicle. In this patient, we used a 9-hole 3.5 mm stainless steel LCP reconstruction plate (Synthes GmbH, Oberdorf, Switzerland) placed antero-superiorly for patient comfort. The plate was contoured along the surface of clavicle in order to purchase all of the locking screws into the position with the greatest pullout strength (maximal clavicle width) in any direction. It was stabilized using only 4 locking screws (2 on medial and 2 on lateral fragments). The screw was placed in a near-near far-far position according to the external fixation principle. After drilling and measuring the bone depth, an appropriate screw length was calculated by adding 2-2.5 cm, which was the approximate distance between the plate and skin, to the aforementioned measured depth. Screws were inserted through the locking hole into the pre-drill hole until it engaged the far cortex. The plate was then lifted up and secured in an appropriate position before continuing to drive the screw heads into the locking holes in order to avoid the excessive penetration of the far cortex and prevent damage to the neurovascular bundle. Once all the screws had been inserted, a stability test was performed by moving the shoulder in all directions under direct inspection and fluoroscopy. Tissue samples were then taken for bacterial culture and the wound was closed.

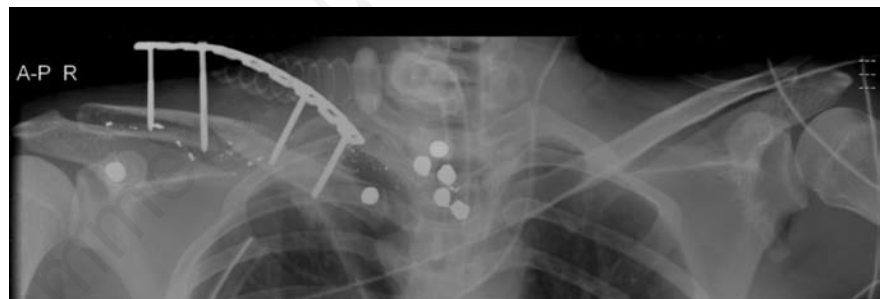## Post-operative care

In this case, no additional debridement was needed because the condition of the wound had gradually improved: exudate discharge had decreased and the soft tissue inflammation resolved. Culture from the second operation showed no bacterial growth. Routine LCP external fixator care was carried out with topi-

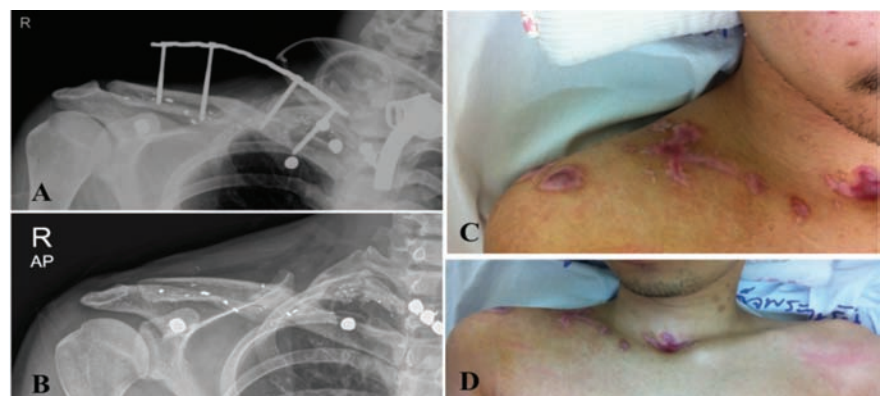
cal Betadine ointment and daily wound dressing. The wound healed within two weeks after the operation. The shoulder was immobilized in an arm sling and the patient was allowed to perform shoulder passive and active-assisted range of motion (ROM) for two weeks, followed by active ROM. Follow-up clinical examination and X-rays of the clavicle were performed periodically. The fracture showed uneventful clinical and radiographic union by eight weeks post surgery; therefore, the LCP was removed under local anesthesia at the bedside. The patient was admitted to our hospital for four months in order to follow intensive rehabilitation and ambulation training. Before discharge, he was able to sit upright independently and bear weight on his right arm with full shoulder range-of-motion. The patient could stand with Hip-Knee-Ankle-Foot orthosis and he was able to walk with a walker and an assistant. No infection or other complication was observed during one year post surgery. Soft tissue profile and follow-up radiographs are shown in Figure 3.



**Figure 1.** Pre-operative X-ray on Day 6 after shotgun injury showing right open comminuted clavicle fracture (white arrow) and non-displaced right second rib fracture (star) with contamination from multiple metallic fragments, hemopneumothorax treated with bilateral ICD and tracheostomy, and multiple pellets on upper thoracic spine, right upper lung and right coracoid.



**Figure 2.** Post-operative X-rays of both clavicles after LCP external fixation revealed stable fixation and nearly anatomical reduction of right clavicle fracture.



**Figure 3.** Post-operative X-rays at (A) eight weeks and (B) one year showing the union of fracture without sign of chronic infection. The photographs of (C) right clavicular area and (D) both clavicles revealed good soft tissue healing and nearly symmetrical clavicle appearance.

**Table 1. Comparison of previous studies using locking compression plate as external fixator in orthopedic surgery.**

Author (year)	Cases	Affected bone	Diagnosis	Implant	Role*	Duration*	Results Infection	Non-union
Apivatthakakul and Sananpanich (2007) <sup>9</sup>	1	Tibia	Open fracture IIIb with bone defect	4.5 mm B-LCP	Def.	10 mo.	0	0
Kloen (2009) <sup>8</sup>	1 3	Clavicle Tibia	Infected non-union	3.5 mm C-LCP 4.5 mm C-LCP	Tem. Tem. (2), Def. (1)	4 mo. (2-6 mo.)	0	0
Woon <i>et al.</i> (2010) <sup>11</sup>	1 1	Tibia	Compartment syndrome Open fracture IIIb	4.5 mm PT-LCP 4.5 mm C-LCP	Def. Def.	8.5 mo. (7-10 mo.)	0	1
Tulner <i>et al.</i> (2012) <sup>10</sup>	7	Distal tibia	Infected posttraumatic problem	LCP metaphyseal plate	Def. (4), Tem. (3)	17.5 wk (6-60 wk)	0	0

\*Number of cases in that specific condition. \*Range of time. B-LCP, broad LCP; C-LCP, conventional LCP; PT-LCP, proximal tibia LCP; Def, using LCP as definitive fixation; Tem, using LCP as temporary fixation; mo, month; wk, week.

## Discussion

Open clavicle fractures are rare injuries and are mostly caused by severe direct penetrating or blunt trauma.<sup>1</sup> Therefore, it is often found to be associated with significant multiple injuries, such as head, thoracic, great vessel, and ipsilateral upper extremity injury.<sup>2,3</sup> Only a few case reports have been previously published in the literature and, to our knowledge, no treatment recommendation or fixation devices have been established for the treatment of this complex injury.

Generally, management of the severe injured patient with open clavicle fracture is based on the patient's overall condition, degree of wound contamination, and severity of fracture and soft tissue injury. In cases of stable hemodynamic status, surgical intervention with debridement and fracture repair are always indicated to prevent infection or non-union. Although ORIF with internal fixation device, such as plate or intramedullary nail, in clavicle fracture has demonstrated promising high union rates,<sup>4</sup> this option is not generally recommended in severe open clavicle injury, especially in cases with significant wound contamination or infection, poor soft tissue condition, and delayed surgical treatment due to risk for further soft tissue damage or skin necrosis. Therefore, external fixation is the most recommended device because it can be used either as temporary fixation in damage control surgery or definitive fixation in order to stabilize the fracture with minimal soft tissue stripping and enable surgeons to perform multiple debridement for treating infection.<sup>5</sup> Results from previous studies showed that external fixation could be used as definitive fixation for open fracture or infected non-union of the clavicle and also resulted in excellent union rate without long-term hardware complications.<sup>5-7</sup> Moreover, the external fixation allows the surgeon to use additional methods such as a suction irrigation system to treat open

infected non-union of the clavicle without risk of infection from an internal fixation device.<sup>7</sup>

Traditionally, external fixator for the clavicle was adapted from a small external fixator system and used 2 or 3 small diameter (3-4 mm) Schanz pins in each medial and lateral fragment to create sufficient stability for fracture fixation. However, this traditional system causes discomfort to the patient on its application because of its bulkiness and the sharp edges of the device, resulting in limited neck motion or an abrasive wound while performing daily activities or sleeping; it can also injure the patient's carer.<sup>8</sup>

Recently, there has been emerging evidence to show that LCP can be applied as an external fixator in subcutaneous bone, such as tibia and clavicle, with a satisfactory outcome.<sup>8-11</sup> (Details of these studies on indications, implants used and results are summarized in Table 1.) This is because LCP has the same angle-stable properties as an external fixator. External application of LCP has many advantages, such as angular stability from locking head mechanism, reduced irritation by a low profile construct compared with a traditional external fixator, and the possibility of contouring the plate along an anatomical area close to the skin. Previous studies demonstrated that LCP external fixation can be used instead of an external fixator in many severe tibia fracture conditions, such as associated compartment syndrome, chronic osteomyelitis and open fracture with large bone defect.<sup>8-12</sup> For clavicle fracture, there has only been one previous study demonstrating the use of a 3.5-mm conventional LCP as a temporary external fixator in open infected non-union clavicular fracture with a successful outcome. However, the authors also noted the disadvantage of using a conventional LCP plate as it is difficult to manipulate or adjust the fixation due to the notable stiffness of the plate. In this present study, we decided to use a 3.5 mm LCP reconstruction plate because it is easier to contour the plate over the clavicle to adjust the direc-

tion of the screws (Figure 2). In case of a larger sized clavicle bone, we believe that a 4.5 mm reconstruction LCP can be used with this technique. Our concern regarding this reconstruction LCP external fixation technique was about it being strong enough to provide long-term stability and withstand external load on the clavicle.

## Conclusions

Reconstruction LCP external fixation is strong enough and can be used as a definitive treatment for open clavicle fracture especially in infected open fracture with concomitant severe soft tissue damage. We believe that this is a useful method that can replace traditional external fixator of the clavicle. However, the pre-operative planning and surgical technique, such as plate length, the number of locking screws, screw positioning, and locking technique, should aim to create stable fixation and avoid excessive penetration.

## References

1. Simon RG, Lutz B. Open clavicle fractures: a case report. *Am J Orthop* 1999;28:301-3.
2. Taitsman LA, Nork SE, Coles CP, et al. Open clavicle fractures and associated injuries. *J Orthop Trauma* 2006;20:396-9.
3. Gottschalk HP, Dumont G, Khanani S, et al. Open clavicle fractures: patterns of trauma and associated injuries. *J Orthop Trauma* 2012;26:107-9.
4. van der Meijden OA, Gaskill TR, Millett PJ. Treatment of clavicle fractures: current concepts review. *J Shoulder Elbow Surg* 2012;21:423-9.
5. Schuind F, Pay-Pay E, Andrianne Y, et al. External fixation of the clavicle for fracture or non-union in adults. *J Bone Joint*

- Surg Am 1988;70:692-5.
6. Strauss EJ, Kaplan KM, Paksima N, Bosco JA 3rd. Treatment of an open infected type IIB distal clavicle fracture: case report and review of the literature. *Bull NYU Hosp Jt Dis* 2008;66:129-33.
  7. Johnson B, Thomas P, McClelland D. Modified Lautenbach technique in the treatment of an open infected non-union of the clavicle-a case report. *Acta Orthop* 2012;83:314-6.
  8. Kloen P. Supercutaneous plating: use of a locking compression plate as an external fixator. *J Orthop Trauma* 2009;23:72-5.
  9. Apivatthakakul T, Sananpanich K. The locking compression plate as an external fixator for bone transport in the treatment of a large distal tibial defect: a case report. *Injury* 2007;38:1318-25.
  10. Tulner SA, Strackee SD, Kloen P. Metaphyseal locking compression plate as an external fixator for the distal tibia. *Int Orthop* 2012;36:1923-7.
  11. Woon CYL, Wong MK, Howe TS. LCP external fixation - external application of an internal fixator: two cases and a review of the literature. *J Orthop Surg Res* 2010;5:19.
  12. Kanchanomai C, Phiphobmongkol V. Biomechanical evaluation of fractured tibia externally fixed with an LCP. *J Appl Biomech* 2012;28:587-92.

Non-commercial use only