

Quality of life after surgery for neuromuscular scoliosis

Peter Obid,¹ Andrea Bevoť,² Almut Goll,³
Corinna Leichtle,³ Nikolaus Wölker,³
Thomas Niemeyer¹

¹Asklepios Klinik St. Georg, Abt. für
Wirbelsäulen- und Skoliosechirurgie,
Hamburg; ²Universitätsklinikum
Tübingen, Klinik für Kinder- und
Jugendmedizin; ³Universitätsklinikum
Tübingen, Klinik für Orthopädie,
Germany

Abstract

Surgery in patients with neuromuscular scoliosis is associated with a higher rate of complications. It is still controversially discussed whether the patients truly benefit from deformity correction. The purpose of this study is to investigate if the quality of life has been improved and if the patients and their caregivers are satisfied with the results of surgery. This is a retrospective clinical outcome study of 46 patients with neuromuscular scoliosis which were treated with primary stable posterior pedicle screw instrumentation and correction. To achieve fusion only autologous bone was used. Follow up was minimum 2 years and maximum 5 years with an average of 36 months. The patients and/or their caregivers received a questionnaire based on the PEDI (pediatric disability inventory) and the GMFS (gross motor function score). The patients (and their caregivers) were also asked if the quality of life has improved after surgery. Only 32 of 46 patients answered the questionnaire. The answers showed a high approval-rate regarding the patients satisfaction with the surgery and the improvement of quality of life. The questionnaire could be answered from 1 (I do not agree) to 4 (I completely agree). The average agreement to the following statements was: i) the quality of life has improved: 3.35; ii) I am satisfied with surgery: 3.95; iii) the operation has fulfilled my expectations: 3.76. The average age at surgery was 12.7 years. The mean pre-operative cobb-angle of the main curve was 83.1° with a correction post-operatively to a mean of 36.9° and 42.6° at final follow-up. That is an average correction of 56.9%. Although spinal fusion in neuromuscular scoliosis is associated with a higher rate of complications our results show that the patients and their caregivers are satisfied with the operation and the quality of life has improved after surgery.

Introduction

Neuromuscular scoliosis is a term that describes several different neurological or muscular disorders that lead to spinal deformities mainly scoliosis or kyphosis or the combination of both spinal deformities. The surgical treatment of a scoliosis caused by such a neuromuscular disorders *e.g.* duchenne's dystrophy is a challenging task and requires a different approach in comparison to the treatment of idiopathic scoliosis. Particular the improvement of quality of life after surgical correction is difficult to assess and remains unpredictable. Therefore the aim of this study was to investigate the quality of life of patients with several different neurological or neuromuscular disorders and severe progressive scoliosis after surgical correction and fusion. The focus was to find out how the parents and caregivers would evaluate the results of surgical correction for neuromuscular scoliosis.

Materials and Methods

This is a retrospective analysis of 46 patients with neuromuscular scoliosis who underwent spinal deformity surgery between 2002 and 2008. The surgeries were performed by one senior surgeon. All patients were mobilized within 24 hours after surgery to prevent respiratory deterioration. No braces were used postoperatively. No bone grafting from the iliac crest was used, only meticulous decortications of the posterior elements with complete removal of the spinous processes. In ten cases we added demineralized bone matrices.

We were unable to achieve a return rate of more than 80%. Therefore we considered the 70% returnees as representative for the whole group.

The study group included 25 male and 21 female patients. Figure 1 shows an exemplary x-ray of a 12 year old boy with a left convex scoliosis and the radiological result after two years. The average age at surgery was 12.7 years (34 months to 31 years). The average follow up was 36 months (24 months to five years).

Figures 2 and 3 show the patients age at surgery and their pathologies leading to neuromuscular scoliosis. All patients were considered as non walker. The small group of patients who were able to stand and perform few steps were not really walker because of their neuromuscular disorder. Therefore we did not differentiate the two groups and we believe that the parameter for measuring the QOL did not differ among the whole group.

Correspondence: Peter Obid, Asklepios Klinik St. Georg, Abt. für Wirbelsäulen- und Skoliosechirurgie, Lohmühlenstraße 5, 20099 Hamburg, Germany.
Tel. +49.40.1818854269 - Fax: + 49.40.1818853079.
E-mail: p.obid@asklepios.com

Key words: neuromuscular scoliosis, spinal fusion, correction, quality of life, outcome.

Conflict of interests: the authors declare no potential conflict of interests.

Received for publication: 21 August 2012.

Revision received: 12 November 2012.

Accepted for publication: 16 December 2012.

This work is licensed under a Creative Commons Attribution NonCommercial 3.0 License (CC BY-NC 3.0).

©Copyright P. Obid *et al.*, 2013
Licensee PAGEPress, Italy
Orthopedic Reviews 2013; 5:e1
doi:10.4081/or.2013.e1

Questionnaire and evaluation

All patients received a questionnaire based on the PEDI (pediatric disability inventory) and the GMFS (gross motor function score) with three different parts: i) the first part asks for the motor function. The patients (and/or their caregivers) should describe motor functions in activities of daily living, *e.g.* the ability to walk and stand before and after surgery; ii) the second part asks for the self-supply of the patients, *e.g.* the ability to brush teeth or comb one's hair; iii) the last part asks for the pain and the patient's satisfaction with the surgery.

The questionnaire consisted of a total of 60 questions. The questions were standardized with four possible answers: i) I do not agree, ii) I predominantly do not agree, iii) I partially agree, iv) I absolutely agree.

The answers showed a high approval-rate regarding the patients satisfaction with the surgery and the improvement of the quality of life. Table 1 shows the results regarding the satisfaction with surgery.

We did not find a correlation between the amount of deformity correction and the improvement of the quality of life. The fusion length did not have an influence on the patients satisfaction either.

Results

Radiological results

The mean pre-operative cobb-angle of the main curve was 83° with correction post-operatively to a mean of 37° and 43° at final follow-

up. That is an average correction of 57%. 37 patients had a pelvic obliquity preoperatively with an average of 15°. This could postoperatively be reduced to an average of 7° (correction of 48%).

Five patients have been fused including the sacrum.

Complications

There were no intraoperative complications. Early complications (defined as complications within 14 days postoperatively that required revision) occurred in five patients. Three had a wound healing disorder. One drainage had to be removed in anesthesia. One patient developed a presacral decubitus.

Late complications occurred in eight patients. In four of them a pedicle screw dislocated. Three patients developed a junctional kyphosis. One patient developed a pseudoarthrosis.

Lumbosacral fusion

Most authors say that a fusion to the lumbar spine is sufficient if the operation is done early and the pelvic obliquity is less than 15-20° (18, 31, 35, 40, 45). In our collective five patients underwent a lumbosacral fusion (included fusion of S1), no iliolumbar fusion was performed. Four of them had a meningocele, one had a muscular dystrophy.

Results of the questionnaire

The results of the questionnaire show a high approval rate regarding the satisfaction with the results, the improvement of the quality of life and the pain (Table 1).

There was no correlation between the radiological results or the length of the fusion and the improvement of the quality of life.

Discussion

The surgical correction of patients with severe neuromuscular diseases and spinal deformity is a challenging task and it remains controversial, whether to operate or not. In our retrospective study we investigated a very heterogeneous group of patients in view of the underlying disorder. The main medical in our group was a progressive spinal deformity (scoliosis) that lead to an impaired sitting ability. Due to the progression of the curve the control over the trunk had a tendency to deteriorate. Therefore it was recommended to stabilize with posterior pedicle screw instrumentation and fixation. Our decision-making process was always multidisciplinary: parents, caregivers, physiotherapists, pediatricians, orthopedic technician and the surgeon.

Our results show that the ability to sit, stand

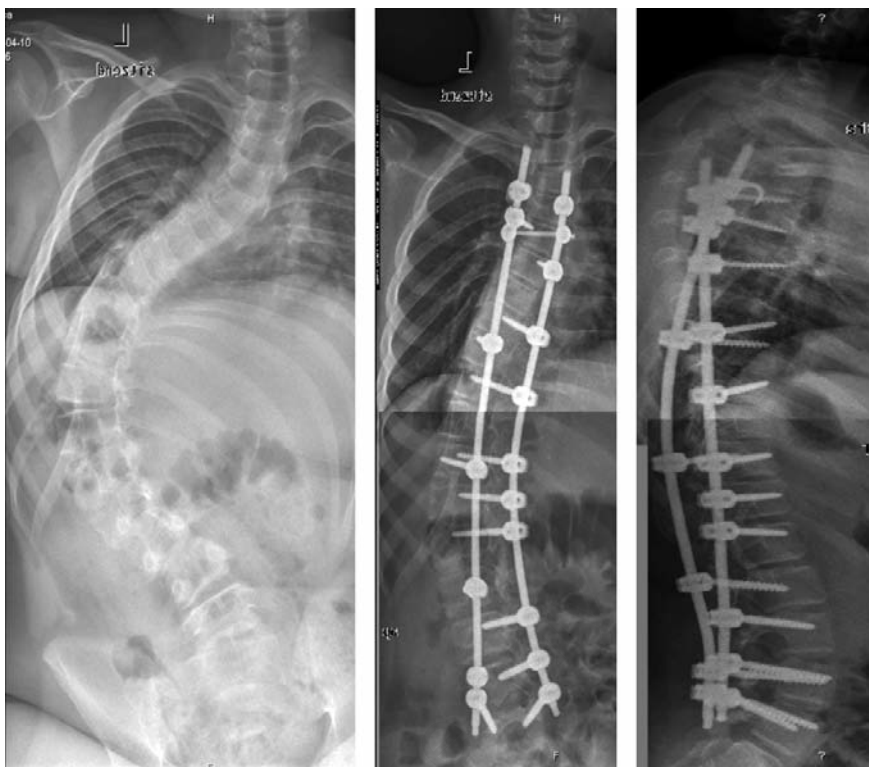

Figure 1. 12 year old patient with a left convex neuromuscular scoliosis. Radiological results two years after dorsal instrumentation spondylodesis.

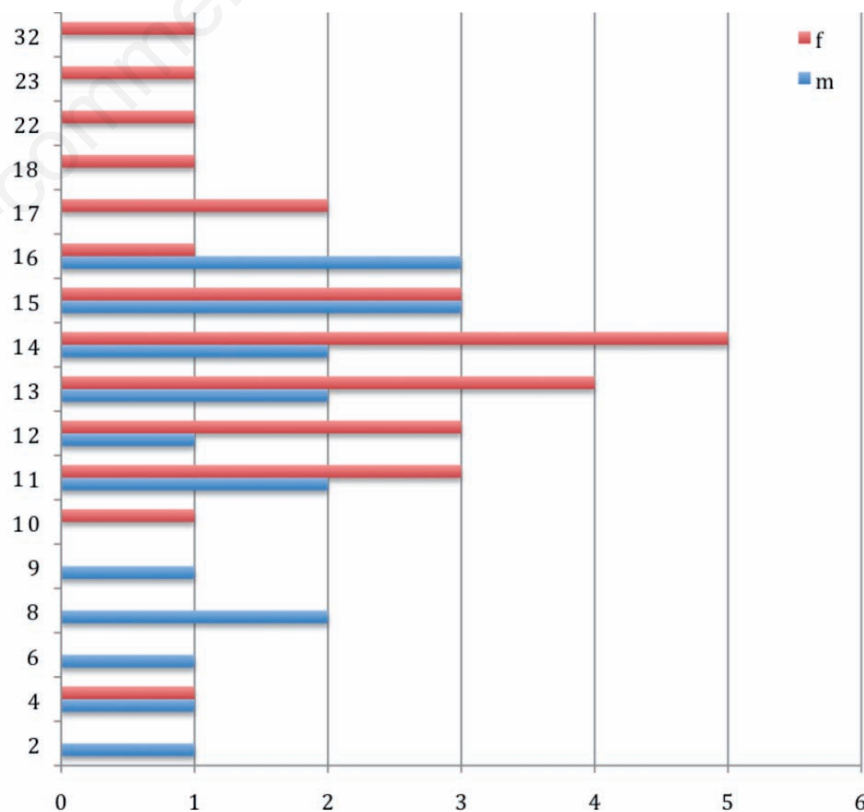


Figure 2. The number of patients and their age at surgery.

or walk has improved in 65% of the patients who could already walk preoperatively. These abilities only improved in 29% of the patients who could not walk preoperatively. These abilities worsened in four patients, all of them have a progressive degenerative disease. If the operation has slowed down the progression cannot be told. Frischhut *et al.* have similar results.¹

Improvement in function after surgery in neuromuscular deformity is still discussed. There are some authors who did not describe any functional benefits from surgery.^{2,3}

In patients with severe neuromuscular scoliosis the pulmonary function can be compromised.⁴ Gill *et al.* showed that surgery in patients with a vital capacity of 40% or less is possible without a higher rate of complications when the patients were treated with non invasive ventilation preoperatively.⁵ Velasco showed that an early operation can slow down the progressive pulmonary dysfunction.⁶

Helenius showed that pain has much more influence on the quality of life than the correction of the deformity.⁷ All patients that had pain preoperatively had significantly less pain postoperatively.

Comstock *et al.* reported that 15% of the caregivers were not satisfied with the results of surgery mainly because the patients either had poor curve correction or developed residual deformity with increases pelvic obliquity.⁸ We did not find any correlation between the amount of deformity correction and the patients and caregivers satisfaction. The overall complication rate of 30% in this study is lower than in previous reports (complication rates of up to 81%).⁹⁻¹⁸

The main objective of this study is to evaluate if the patient's quality of life did improve after deformity correction.

The results are similar to other studies in demonstrating patient and parent/caregiver satisfaction.

The patients and/or their caregivers were highly satisfied with the operation (average affirmation 3.95 of 4). In their opinion the operation did improve the quality of life (average affirmation 3.35 of 4); 90% of the patients and/or their caregivers would do the operation again. The patients benefit from the correction of neuromuscular deformities. All radiological and functional parameters improved significantly as did the self-evaluation.

The surgical correction of neuromuscular deformities requires a careful analysis of all social and medical aspects preoperatively. Surgical correction of neuromuscular scoliosis provides a benefit in quality of life and function while such operations are only manageable, when a multidisciplinary decision-making process takes place and the treating physician, the physiotherapist, the anesthetist and the surgeon work hand in hand to manage these patients.

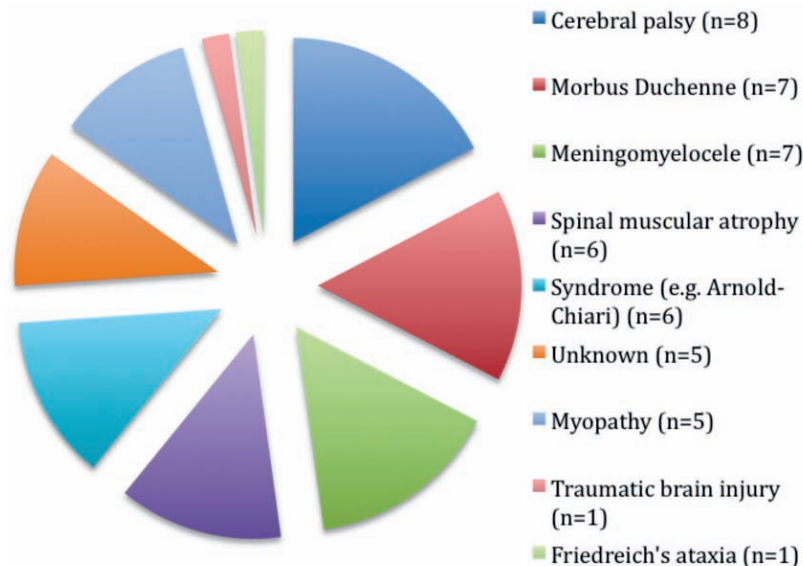


Figure 3. The pathologies of the patients (n=46).

Table 1. Results of the questionnaire: 1= I do not agree, 2= I predominantly agree, 3= I partially agree, 4= I absolutely agree.

	Mean value of the answers	Standard deviation
Satisfied with the operation	3.95	0.22
Operation answered expectations	3.76	0.70
Quality of life improved	3.35	0.89
Less pain	3.29	1.27
Easier nursing	2.58	1.16
Improvement of self-perception	3.53	1.06

Conclusions

In summary we confirm the results of the current literature and we believe that our good results show that in a multidisciplinary setting even children with severe neuromuscular deformities and handicaps can be treated surgically successful.

References:

1. Frischhut B, Sterzinger W, Rachbauer R, et al. Surgical treatment of neuropathic scoliosis: morphologic and functional outcome. *Arch Orthop Trauma Surg* 1997;116: 367-72.
2. Kalen V, Conklin MM, Sherman FC. Untreated scoliosis in severe cerebral palsy. *J Pediatr Orthop* 1992;12:337-40.
3. Cassidy C, Craig CL, Perry A, et al. A reassessment of spinal stabilization in severe cerebral palsy. *J Pediatr Orthop* 1994;14:731-9.
4. Zeller R. Neuromuskuläre Skoliosen - Behandlungsverlauf und Therapieprinzipien. *Orthopäde* 2000;29:518-23.
5. Gill I, Eagle M, Mehta JS, et al. Correction of neuromuscular scoliosis in patients with preexisting respiratory failure. *Spine* 2006;31:2478-83.
6. Velasco MV, Colin A, Zurakowski D, et al. Posterior spinal fusion for scoliosis in duchenne muscular dystrophie diminishes the rate of respiratory decline. *Spine* 2007; 32:459-65.
7. Helenius I, Remes V, Lamberg T, et al. Long term quality of life after surgery for adolescent idiopathic scoliosis and spondylolisthesis. *J Bone Joint Surg* 2008;90:1231-9.
8. Comstock CP, Leach J, Wenger DR. Scoliosis in total-boy-involvement cerebral palsy: analysis of surgical treatment and patient and caregiver satisfaction. *Spine* 1998;23:1412-24.
9. Boachie-Adjei O, Lonstein JE, Winter RB.

- Management of neuromuscular spinal deformities with Luque segmental instrumentation. *J Bone Joint Surg Am* 1989;71: 548-62.
10. Broom MJ, Banta JV, Renshaw TS. Spinal fusion augmented by luque-rod segmental instrumentation for neuromuscular scoliosis. *J Bone Joint Surg Am* 1989;71:32-44.
 11. Allen BL Jr, Ferguson RL. L-rod instrumentation for scoliosis in cerebral palsy. *J Pediatr Orthop* 1982;2:87-96.
 12. Bell DF, Moseley CF, Koreska J. Unit rod segmental spinal instrumentation in the management of patients with progressive neuromuscular spinal deformity. *Spine* 1989;14:1301-7.
 13. Brown JC, Swank S, Specht L. Combined anterior and posterior spine fusion in cerebral palsy. *Spine* 1982;7:570-3.
 14. Lonstein JE, Akbarnia A. Operative treatment of spinal deformities in patients with cerebral palsy or mental retardation. An analysis of one hundred and seven cases. *J Bone Joint Surg Am* 1983;65:43-55.
 15. Rinsky LA. Surgery of spinal deformity in cerebral palsy. Twelve years in the evolution of scoliosis management. *Clin Orthop Relat Res* 1990;253:100-9.
 16. Tsirikos AI, Chang WN, Dabney KW, Miller F. Comparison of parents' and caregivers' satisfaction after spinal fusion in children with cerebral palsy. *J Pediatr Orthop* 2004;24:54-8.
 17. Benson ER, Thomson JD, Smith BG, Banta JV. Results and morbidity in a consecutive series of patients undergoing spinal fusion for neuromuscular scoliosis. *Spine* 1998;23:2308-17.
 18. Lipton GE, Miller F, Dabney KW, et al. Factors predicting postoperative complications following spinal fusions in children with cerebral palsy. *J Spinal Disord* 1999; 12:197-205.

Non-commercial use only