

Regenerate augmentation with bone marrow concentrate after traumatic bone loss

Jan Gessmann,¹ Manfred Köller,²
Holger Godry,¹

Thomas Armin Schildhauer,¹
Dominik Seybold¹

¹Department of General and Trauma
Surgery and ²Department of Surgical
Research, BG University Hospital
Bergmannsheil, Bochum, Germany

Abstract

Distraction osteogenesis after post-traumatic segmental bone loss of the tibia is a complex and time-consuming procedure that is often complicated due to prolonged consolidation or complete insufficiency of the regenerate. The aim of this feasibility study was to investigate the potential of bone marrow aspiration concentrate (BMAC) for percutaneous regenerate augmentation to accelerate bony consolidation of the regenerate. Eight patients (age 22-64) with an average posttraumatic bone defect of 82.4 mm and concomitant risk factors (nicotine abuse, soft-tissue defects, obesity and/or circulatory disorders) were treated with a modified Ilizarov external frame using an intramedullary cable transportation system. At the end of the distraction phase, each patient was treated with a percutaneously injection of autologous BMAC into the centre of the regenerate. The concentration factor was analysed using flow cytometry. The mean follow up after frame removal was 10 (4-15) months. With a mean healing index (HI) of 36.9 d/cm, bony consolidation of the regenerate was achieved in all eight cases. The mean concentration factor of the bone marrow aspirate was 4.6 (SD 1.23). No further operations concerning the regenerate were needed and no adverse effects were observed with the BMAC procedure. This procedure can be used for augmentation of the regenerate in cases of segmental bone transport. Further studies with a larger number of patients and control groups are needed to evaluate a possible higher success rate and accelerating effects on regenerate healing.

Introduction

Distraction osteogenesis for segmental bone defect reconstruction is an established procedure. However, the long duration of the time in external fixation is often cause of considerable morbidity and high complication

rates. The therapeutic potential of facilitating callus maturation lies in both reducing the healing index in more basic cases and increasing the success rates in more difficult cases. Currently, augmentation with percutaneously applied adjuvants to reduce consolidation time has been designated as one of the major goals for future research in distraction osteogenesis.¹ There is already clinical evidence that the application of cells can accelerate healing of the regenerate: Kitoh *et al.*² were able to demonstrate that the percutaneous transplantation of culture-expanded bone marrow cells and platelet-rich plasma accelerates bone regeneration during distraction osteogenesis and thereby reduce overall complication rates.² However, the directives for the expansion, differentiation and re-transplantation of bone marrow cells in Europe follow certain, very strict requirements.³ There are also potential risks, such as contamination or depletion of proliferative capacity, as well as additional costs, including personnel expenses, culture instruments, chemicals, and contamination tests.^{2,4} Furthermore, a one-step procedure with on-table preparation for immediate transplantation may prevent complications related to a reduced quality of the transplanted cells, such as pre-aging, reduced viability, or dedifferentiation (all of which are associated with *in vitro* cultivation).^{5,6}

In the treatment of aseptic non-unions, percutaneous injection of autologous bone marrow aspirate has been shown to be clinically effective.^{7,8} Hernigou *et al.* were able to demonstrate that efficacy seems to be related to the number of progenitor cells in the graft.⁹ Therefore, the authors concentrated the bone marrow aspirate for increasing the number of progenitor cells before intraosseous reinjection at the site of non-union.⁹ Recently, there have been reports with promising results on transplantation of bone marrow concentrate for poor-healing bone sites.¹⁰⁻¹³ The advantage of concentrated bone marrow aspirate relies on the possibility of on-table preparation and reinjection in one operation without the need to take the cells from the operation room into a laboratory. The positive results of this new technique together with the on-table preparation were the motivation to test the feasibility for distraction osteogenesis.

Materials and Methods

This prospective study was approved by the ethics committee of the Ruhr Universität Bochum, Germany (ethical approval number 3594-09). All patients gave their written consent to participate in this study.

Between June 2009 and August 2010, two female and six male patients aged 22-64

Correspondence: Jan Gessmann, Department of General and Trauma Surgery, BG University Hospital Bergmannsheil, Bürkle-de-la-Camp-Platz 1, 44789 Bochum, Germany.
Tel. +49.234.302.3425.
E-mail: jan.gessmann@bergmannsheil.de

Key words: distraction osteogenesis, bone marrow, posttraumatic bone defect, mesenchymal stem cell.

Received for publication: 4 February 2012.
Accepted for publication: 4 March 2012.

This work is licensed under a Creative Commons Attribution NonCommercial 3.0 License (CC BY-NC 3.0).

©Copyright J. Gessmann *et al.*, 2012
Licensee PAGEPress, Italy
Orthopedic Reviews 2012; 4:e14
doi:10.4081/or.2012.e14

(mean 44.4) years with posttraumatic bone defects of the tibia were admitted to our clinic (Table 1). All patients were treated with different operative procedures before attending our clinic, with a mean of 4.8 prior operative procedures. Patients who reported prior treatment after open trauma and posttraumatic infection were treated with debridement, bone resection and soft-tissue coverage by local and free flaps and temporary stabilisation with a monolateral fixator (Figure 1). The sizes of the bone defects were between 44 and 126 mm (mean 82.4 mm). A free flap transfer was necessary in two patients (Patients 1 (*latissimus dorsi* flap) and 5 (anterolateral thigh (ALT) and *latissimus dorsi* flap) and local flap coverage in five patients (Patients 2-4, 7, 8). After soft-tissue healing, the monolateral external fixation was replaced by an Ilizarov ring fixator. Segmental bone transport was performed using an intramedullary cable transport system (Figure 2). For distraction osteogenesis, percutaneous osteotomy of the proximal tibia (Gigli saw) was performed in the seven cases of antero-grade transport; percutaneous osteotomy of the distal tibia was performed in the case of retrograde transport. The bone segment transport was started after a delay of 7 days. The distraction rate was 1 mm/day in the antero-grade transport and 0.5 mm in the one patient with retrograde transport. Six patients were heavy smokers before bone transport, and four of them continued to smoke throughout the entire treatment phase (Patients 1, 4, 5, 6).

Patients were taught to work the transport clickers by themselves during the first days after the operation and were seen every two weeks for X-ray control of distraction progress. At the time of the docking of the transported segment, the patients were admitted to the hospital. The cable system and transport clickers

were removed, and the transport-segment was fixed to the frame with K-wires and/or half pins in the operating room. Local debridement of the docking zone and autologous bone grafting from the iliac crest were performed in each patient. Before harvesting the autologous bone from the iliac crest, a total of 60 mL bone marrow aspirate was obtained by Jamshidi vacuum aspiration from the same iliac crest. Thereby, only a few millilitres were aspirated at once before the aspiration needle was placed in different areas of the iliac crest to ensure a cell-rich aspirate. The bone marrow aspiration concentrate (BMAC) was produced via density gradient centrifugation using the Smartprep2™ centrifuge (Harvest Technologies, Plymouth, MA, USA), in accordance with the manufacturer's directions in the operation room. After centrifugation, the plasma was removed, and cells were resuspended, leaving a total volume of 8 mL. Two mL of autologous thrombin were added to the cell suspension before transplantation into the regenerate. The Jamshidi needle was used as a syringe and was placed under X-ray control percutaneously in the centre of the regenerate, and the BMAC-thrombin-suspension was slowly injected. Both aspirate and concentrate (2 mL were saved of each sample for *in vitro* analyses) were analysed using flow cytometry (FACS) regarding the containing cells. The concentration factor was calculated by the cell count-quotient BMAC/aspirate after the centrifugation procedure.

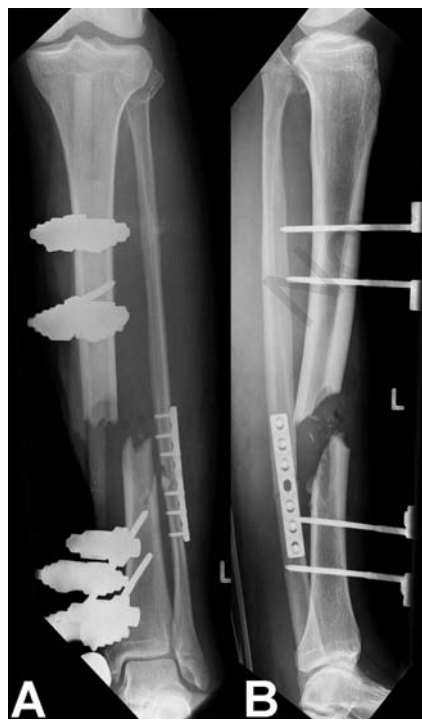

Figure 1. X-rays (anterior (A) and lateral view (B)) of Patient 7 at the day of admission with central bone defect after an open fracture of the tibia (Gustilo type III B).

Patients were regularly seen every two weeks for frame and soft-tissue control and for retightening of the Ilizarov screws. X-rays in two planes were taken every four weeks to evaluate the healing of the docking zone and the regenerate. Frames were removed when bony healing with at least three cortices was present in both the regenerate and the docking zone. Peri- and postoperative complications were divided to frame-associated complication, BMAC transplantation-associated complications and complications not related to the procedures. The healing index (=time in frame (in days)/length of regenerate (in cm)) and the consolidation index (=time in frame after distraction phase [in days]/length of the regenerate (in cm)) 3after BMAC transplantation were calculated.

Results

Bony consolidation of the regenerate was achieved in all patients. The mean healing index was 36.9 d/cm (range 27.9 to 48.6) while the mean consolidation index was 23.1 d/cm (range 14.8 to 32.7; Table 1). The mean distraction phase lasted for 107 (60-156) days. The longer distraction phase in relation to the mean defect size was caused by different factors. Retrograde transport (Patient 2) was performed with 0.5 mm/d, which doubled the distraction phase in this patient. Furthermore, the longer defect sizes (Patients 3-8) required an exchange of the distraction clickers with re-tensioning of the cable. During that procedure,

Table 1. Mean bone defect size, soft tissue procedure, healing index and consolidation index.

Patient	Age	Sex	Bone defect in mm	Additional soft tissue procedures	HI in d/cm	CI in d/cm	Follow up in months
1	51	m	60	Latissimus dorsi free flap	42.7	32.7	14
2	44	m	44	Local flap	48.6	25.4	10
3	50	f	85	Local flap	28.5	16.9	13
4	42	m	97	Local flap	43.7	31.3	15
5	42	m	96	Anterior lateral thigh free flap, Latissimus dorsi free flap	40.1	23.9	13
6	40	m	81	None	35.2	22.2	9
7	22	m	70	Local flap	27.9	14.8	5
8	64	f	126	Local flap	28.7	17.5	4

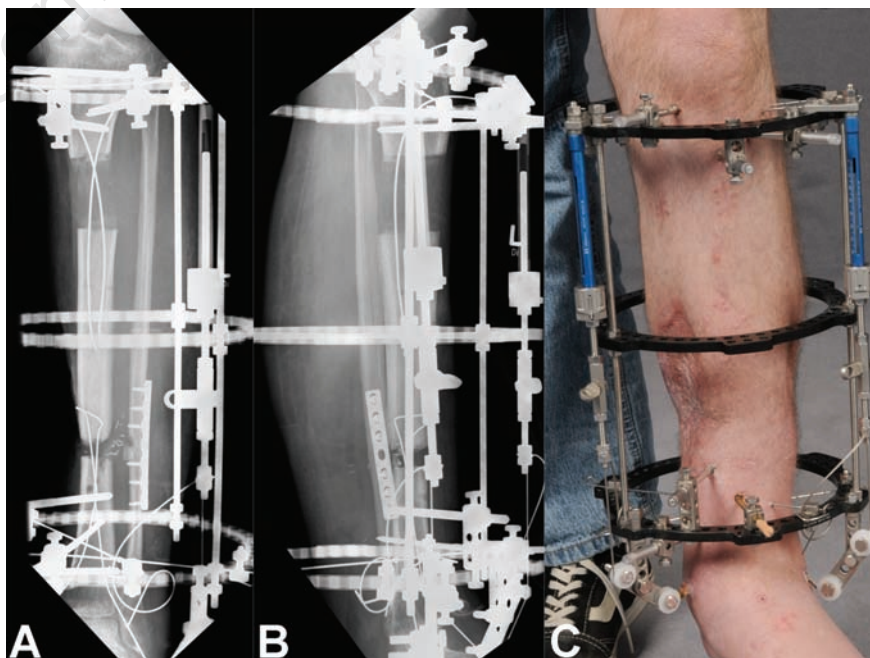


Figure 2. X-rays (A, B) of Patient 7 during the distraction phase (anterograde bone segmental transport) and clinical picture (C) of the Ilizarov external frame with the applied cable system and transport clickers.

the bone segment slipped back several mm in the reverse-direction of transport. During the distraction phase, patient 4 suffered from a distal femoral fracture due to an accidental fall on the same leg. This fracture was fixed with a percutaneous locking-plate system (NCB, Zimmer, USA). In Patient 5, the previously transplanted ALT-flap showed partial necrosis, which exposed the bone ends in the docking zone. Before the docking procedure, coverage with a latissimus dorsi flap was necessary, and the BMAC procedure was performed after soft-tissue healing to reduce the risk of infection.

Local pin infections were seen in six patients (Patient 2, 4, 5-8) and were treated with local skin incision and oral antibiotics. No pin or wire removal was necessary. With regard to major complications, Patient 2 displayed non-union of the docking site. The patient refused any further surgery and was treated with a leg brace. However, the regenerate showed sound bony healing.

At the mean follow-up of 10.4 months after removal of the frame, all patients except patient 2 were able to walk at full weight-bearing without the help of crutches. Figures 3 and 4 show the radiological results of Patient 7 and 8. No adverse effects of cell injection into the regenerate were seen. The *in vitro* analysis of aspirate and BMAC showed that the percentage of cells was not changed significantly by the centrifugation process (percentage of cells before/after centrifugation: granulocytes 75.9/76.6; lymphocytes 17.7/16.9; monocytes 3.1/3.6; CD34⁺ 1.1/1.3; CD45/CD90⁺ 0.76/0.93). The average concentration factor of the BMAC compared to the aspirate was 4.6 (SD 1.23).

Discussion

Several experimental studies demonstrated that transplantation of progenitor cells into a bone-healing site improves bone formation.^{4,14,15} This suggests that in many situations tissue and bone repair may be limited by the presence and number of local progenitor cells.⁴ There are different approaches to increase the population of these cells, but there is preliminary evidence that local application of these cells may be of benefit:^{16,17} either immediate implantation of harvested cells from bone marrow aspiration or transplantation of cells after culture expansion and differentiation. The latter approach is already in clinical use for cartilage repair¹⁸⁻²⁰ but has also been proven clinically effective in distraction osteogenesis.^{2,21-23} Connolly *et al.*⁷ and Garg *et al.*⁸ suggested a beneficial effect of the percutaneous transplantation of autologous bone marrow aspirate in cases of non-union in long bones. Hernigou *et al.* demonstrated that by centrifugation of bone marrow aspirate, the mononuclear cells can be concentrated, resulting in further enhancements of osteogenesis.⁹ The effectiveness of the BMAC procedure in harvesting mononuclear cells, including mesenchymal stem cells, has been demonstrated in different studies.^{10,24,25} Jäger *et al.* showed that relevant amounts of potent mesenchymal stem cells, which differentiate into osteoblasts *in vitro*, can be harvested with the BMAC system.¹⁰ The mean concentration factor of 4.6 that we found in the present study lies between the results presented by Hermann *et al.* (mean factor of

4.4)²⁵ and Jäger *et al.* (mean factor of 5.2).¹⁰ Very recently, other authors have demonstrated beneficial effects on bone healing in patients with bone cysts, osteo-necrosis and non-unions with the transplantation of BMAC.^{5,10,11,13,26} To the knowledge of the authors, the procedure has not been described for distraction osteogenesis.

Three essentials constituents have been assumed besides biomechanical stability and vascularization in accelerating new bone formation (referred to as the diamond concept): growth factors, osteoprogenitor cells and extracellular matrix/natural scaffold.²⁷ The BMAC system provides the first two constituents. The third - the natural scaffold - is generated during the distraction process: During the distraction phase a fibrovascular lattice is generated between the two distracted bone ends, which consist of longitudinally oriented fibrous connective tissue with a protective covering membrane.^{28,29} The BMAC was injected at the end of the distraction phase into this membranaceous tube that is assumed to function as a natural scaffold for the cell suspension. It has been shown that a so-called growth zone forms in the centre of the lengthening segment, in which no ossification occurs until the consolidation phase begins.^{28,29} In a patient treated previously to the present study we could visualize the diffusion of non-concentrated iliac crest blood mixed with a contrast medium in the centre of the regenerate (Figure 5). Furthermore, the addition of autologous thrombin transferred the fluid cell suspension into a viscous, gel-like constitution, and may lead to a local adher-

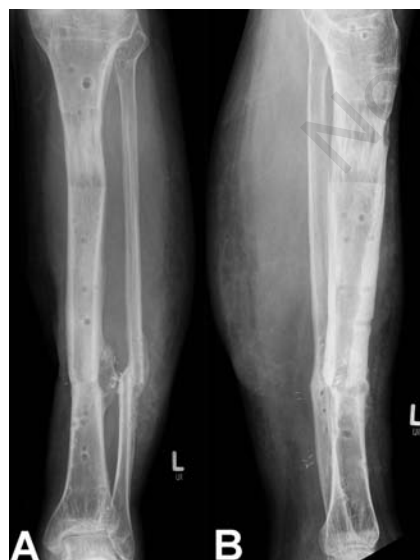

Figure 3. X-rays of Patient 7 four months after frame removal with bony consolidation both of the regenerate and the distal docking site.

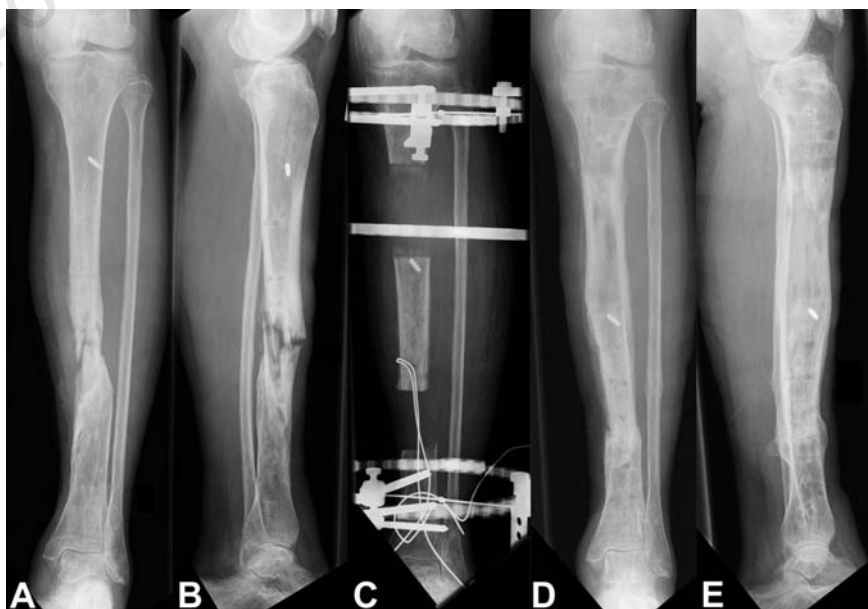


Figure 4. X-rays of Patient 8 with a pathologic fracture due to a chronic osteomyelitis at the day of admission (A, B) during transportation (C) and five months after frame removal (C, D, E).




Figure 5. Intraoperatively taken X-ray picture showing the diffusion of iliac crest blood aspirate mixed with contrast medium in the centre of the regenerate in a patient treated with segmental bone transport.

ence of the injected cells as described similarly by Schmelzeisen *et al.*³⁰ for maxillary sinus application.

This feasibility study suffers from the small number of patients and a missing control group, which is a problem of many cell-based clinical studies.^{5,9,10,30,31} Bone healing in distraction osteogenesis is a complex process that is dependent on various parameters such as age, epidemiology of bone loss, soft-tissue envelope, and fixation device. This makes it even more difficult to compare the healing or consolidation index with other studies. In general, longer healing indices have been reported for segmental transports in posttraumatic and/or (post-)infected patients compared to callus distraction in non-injured regions. Under these difficult conditions, healing indices up to 4.6 month/cm and the time in frame up to 54 months have been reported, and the rate of callus insufficiency is significantly higher.³²⁻³⁵ Especially poor soft-tissue conditions, restricted blood supply and nicotine abuse are risk factors. In cases of long-size transports, the docking site usually heals long before consolidation of regenerate occurs.¹ Although all patients presented with posttraumatic bone loss and all but one needed additional flap coverage, we did not observe insufficiency of the regenerate. Four patients also continued to smoke throughout the treatment. The mean HI of 36.9 d/cm and CI of 23.1 d/cm appear rather short in comparison to the above named studies concerning posttraumatic bone defects but must be interpreted with care due to limitations of the present feasibility study.

Conclusions

Accelerating the consolidation phase during distraction osteogenesis and prevent insuffi-

ciency of the callus is of great need in clinical practice. The safety demands for an augmentation procedure must be very strict; the technique needs to be of minimal risk and minimal invasiveness, without compromising the regenerated callus and surrounding soft tissues. Based on the recent literature and these preliminary results, this seems to apply for the BMAC procedure. We did not detect any adverse effects on the side of harvesting or at the regenerate. Further studies with a larger number of patients and a control group are needed to evaluate the effects on accelerated regenerate healing.

References

1. Watson JT, Kuldjanov, D. Bone Defects. In: Rozbruch SR, Ilizarov, S., editor. Limb Lengthening and Reconstruction Surgery. New York: Informa Healthcare; 2007. p. 185-202.
2. Kitoh H, Kawasumi M, Kaneko H, Ishiguro N. Differential effects of culture-expanded bone marrow cells on the regeneration of bone between the femoral and the tibial lengthenings. *J Pediatr Orthop* 2009;29: 643-9.
3. Kasten P, Bernstein P, Biewener A, et al. [Perspectives of clinical stem cell therapy in the treatment of musculoskeletal diseases in Germany]. *Z Orthop Unfall* 2010;148:149-54. [Article in German]
4. Patterson TE, Kumagai K, Griffith L, Muschler GF. Cellular strategies for enhancement of fracture repair. *J Bone Joint Surg Am* 2008;90Suppl:111-9.
5. Jager M, Jelinek EM, Wess KM, et al. Bone marrow concentrate: a novel strategy for bone defect treatment. *Curr Stem Cell Res Ther* 2009;4:34-43.
6. Song L, Tuan RS. Transdifferentiation potential of human mesenchymal stem cells derived from bone marrow. *FASEB J* 2004;18:980-2.
7. Connolly JF, Guse R, Tiedeman J, Dehne R. Autologous marrow injection as a substitute for operative grafting of tibial nonunions. *Clin Orthop Relat Res* 1991; 266:259-70.
8. Garg NK, Gaur S, Sharma S. Percutaneous autogenous bone marrow grafting in 20 cases of ununited fracture. *Acta Orthop Scand* 1993;64:671-2.
9. Hernigou P, Poignard A, Beaujean F, Rouard H. Percutaneous autologous bone-marrow grafting for nonunions. Influence of the number and concentration of progenitor cells. *J Bone Joint Surg Am* 2005;87:1430-7.
10. Jager M, Herten M, Fochtmann U, et al. Bridging the gap: Bone marrow aspiration concentrate reduces autologous bone grafting in osseous defects. *J Orthop Res* 2010;29:173-80.
11. Garnavos C, Mouzopoulos G, Morakis E. Fixed intramedullary nailing and percutaneous autologous concentrated bone-marrow grafting can promote bone healing in humeral-shaft fractures with delayed union. *Injury* 2010;41:563-7.
12. Murawski CD, Kennedy JG. Percutaneous internal fixation of proximal fifth metatarsal Jones fractures (zones II and III) with Charlotte Carolina screw and bone marrow aspirate concentrate: an outcome study in athletes. *Am J Sports Med* 2011;39:1295-301.
13. Wang BL, Sun W, Shi ZC, et al. Treatment of nontraumatic osteonecrosis of the femoral head with the implantation of core decompression and concentrated autologous bone marrow containing mononuclear cells. *Arch Orthop Trauma Surg* 2010;130:859-65.
14. Muschler GF, Nitto H, Matsukura Y, et al. Spine fusion using cell matrix composites enriched in bone marrow-derived cells. *Clin Orthop Relat Res* 2003;407:102-18.
15. Granero-Molto F, Weis JA, Miga MI, et al. Regenerative effects of transplanted mesenchymal stem cells in fracture healing. *Stem Cells* 2009;27:1887-98.
16. Quarto R, Mastrogiacomo M, Cancedda R, et al. Repair of large bone defects with the use of autologous bone marrow stromal cells. *N Engl J Med* 2001;344:385-6.
17. Clines GA. Prospects for osteoprogenitor stem cells in fracture repair and osteoporosis. *Curr Opin Organ Transplant* 2010;15:73-8.
18. Knutsen G, Engebretsen L, Ludvigsen TC, et al. Autologous chondrocyte implantation compared with microfracture in the knee. A randomized trial. *J Bone Joint Surg Am* 2004;86A:455-64.
19. Horas U, Pelinkovic D, Herr G, et al. Autologous chondrocyte implantation and osteochondral cylinder transplantation in cartilage repair of the knee joint. A prospective, comparative trial. *J Bone Joint Surg Am* 2003;85A:185-92.
20. Kon E, Gobbi A, Filardo G, et al. Arthroscopic second-generation autologous chondrocyte implantation compared with microfracture for chondral lesions of the knee: prospective nonrandomized study at 5 years. *Am J Sports Med* 2009;37: 33-41.
21. Kitoh H, Kitakoji T, Tsuchiya H, et al. Transplantation of marrow-derived mesenchymal stem cells and platelet-rich plasma during distraction osteogenesis—a preliminary result of three cases. *Bone* 2004; 35:892-8.
22. Kitoh H, Kitakoji T, Tsuchiya H, et al.

- Transplantation of culture expanded bone marrow cells and platelet rich plasma in distraction osteogenesis of the long bones. *Bone* 2007;40:522-8.
23. Kitoh H, Kitakoji T, Tsuchiya H, et al. Distraction osteogenesis of the lower extremity in patients with achondroplasia/hypochondroplasia treated with transplantation of culture-expanded bone marrow cells and platelet-rich plasma. *J Pediatr Orthop* 2007;27:629-34.
 24. Sauerbier S, Stricker A, Kuschnierz J, et al. In vivo comparison of hard tissue regeneration with human mesenchymal stem cells processed with either the FICOLL method or the BMAC method. *Tissue Eng Part C Methods* 2010;16:215-23.
 25. Hermann PC, Huber SL, Herrler T, et al. Concentration of bone marrow total nucleated cells by a point-of-care device provides a high yield and preserves their functional activity. *Cell Transplant* 2008;16:1059-69.
 26. Di Bella C, Dozza B, Frisoni T, et al. Injection of Demineralized Bone Matrix With Bone Marrow Concentrate Improves Healing in Unicameral Bone Cyst. *Clin Orthop Relat Res* 2010;468:3047-55.
 27. Calori GM, Giannoudis PV. Enhancement of fracture healing with the diamond concept: The role of the biological chamber. *Injury* 2011;42:1191-3.
 28. Aronson J, Harrison BH, Stewart CL, Harp JH, Jr. The histology of distraction osteogenesis using different external fixators. *Clin Orthop Relat Res* 1989;241:106-16.
 29. Bernstein A, Mayr HO, Hube R. Can bone healing in distraction osteogenesis be accelerated by local application of IGF-1 and TGF-beta1? *J Biomed Mater Res B Appl Biomater* 2010;92:215-25.
 30. Schmelzeisen R, Gutwald R, Oshima T, et al. Making bone II: maxillary sinus augmentation with mononuclear cells-case report with a new clinical method. *Br J Oral Maxillofac Surg* 2010;49:480-2.
 31. Fayaz HC, Giannoudis PV, Vrahas MS, et al. The role of stem cells in fracture healing and nonunion. *Int Orthop* 2011;35:1587-97.
 32. Mekhail AO, Abraham E, Gruber B, Gonzalez M. Bone transport in the management of posttraumatic bone defects in the lower extremity. *J Trauma* 2004;56:368-78.
 33. Fischgrund J, Paley D, Suter C. Variables affecting time to bone healing during limb lengthening. *Clin Orthop Relat Res* 1994;301:31-7.
 34. Reigstad A. Soft tissue defects and bone loss in tibial fractures--treatment with free flaps and bone transport. *Acta Orthop Scand* 1997;68:615-22.
 35. Liidakis E, Kenawey M, Krettek C, et al. Comparison of 39 post-traumatic tibia bone transports performed with and without the use of an intramedullary rod: the long-term outcomes. *Int Orthop* 2010;35:1397-402.