

Multiple pelvic insufficiency fractures in rheumatoid patients with mutilating changes

Shigeo Fukunishi, Tomokazu Fukui,
Shoji Nishio, Fumiaki Imamura,
Shinichi Yoshiya

Department of Orthopaedic Surgery
Hyogo College of Medicine, Nishinomiya
City, Hyogo, Japan

Abstract

Multiple insufficiency fractures occurred in two patients with mutilating rheumatoid arthritis (RA), leading to substantial disabilities. Both patients received long-term oral glucocorticoid therapy and underwent multiple lower-extremity surgeries such as total hip arthroplasty (THA) or Total knee arthroplasty (TKA). The multiple fractures were located in the pelvis and lumbo-sacral region. Fractures in both patients were treated conservatively. Although bony union and resumption of activities were achieved in one patient, the other patient was not able to resume ambulation. For RA patients with combined risk factors for insufficiency fractures, aggressive preventive intervention and careful clinical assessment for early detection and management are warranted.

Introduction

An insufficiency fracture is defined as a type of stress fracture caused by physiological stress applied to weak bone. Although various locations in both the trunk and extremities are involved, the pelvis is one of the predominant sites of occurrence.^{1,9} The clinical features of this fracture are characterized by the gradual onset of vague pain, and physical findings that are nonspecific. Since plain radiographs often fail to reveal the fracture or show only subtle findings at the initial stage, detailed image examinations such as computed tomographic (CT) scans and MRI or bone scintigraphy are necessary to make an early diagnosis. Therefore, this fracture can be overlooked with a substantial delay in diagnosis. Delay in diagnosis and initiation of proper management can lead to substantial and prolonged disability. Older women with postmenopausal osteoporosis are most predominantly affected by insufficiency fractures.^{1,3} In addition, patients with mutilating type RA who often receive long-term glucocorticoid treatment and undergo

multiple surgeries^{10,11} are also in a high-risk group. In this report, we describe the clinical course of two mutilating type RA patients presenting with multiple insufficiency fractures of the pelvis. Resolution of symptoms was delayed in both patients resulting in prolonged morbidity and subsequent disability.

Case Report

Case 1

A 56-year-old woman presented with vague low back pain without a history of trauma. She was diagnosed with RA at the age of 29 years. To medicate against RA she had received glucocorticoid (prednisone, 10 mg/day), methotrexate (6 mg/week) and nonsteroidal anti-inflammatory drugs (NSAIDs) for more than 10 years. She had also undergone multiple surgical procedures in the lower extremities including a right hip hemiarthroplasty with a bipolar prosthesis, a left THA, bilateral TKAs, a right ankle arthrodesis, and resection arthroplasties of the bilateral toes (Figure 1A). Physical examination revealed mild limitation of trunk motion due to pain. Radiographs of both hands showed typical mutilating change corresponding to stage V of RA in the Larsen classification (Figure 1B).¹² However, routine radiographic examination of the spine and the pelvis showed no apparent bony abnormality. Based on these clinical findings, a definite cause of the pain could not be identified and follow-up was continued without specific treatment. Thereafter, her low back pain gradually increased to a level interfering with her ambulation. Three weeks after initial presentation she was unable to walk, and was admitted to our hospital with low back pain. CT scan of the sacrum after admission showed a linear fracture gap in the bilateral sacral alae and Denis type II fracture in the right sacrum (Figure 1C). Radiographs of the lumbar spine showed fractures in both transverse processes of the 5th vertebra (Figure 1D). She was treated conservatively with bed rest and subsequent physical therapy with resultant resolution of pain and recovery of daily living activity over a period of three months. However, two months later, she complained of left groin pain without a history of trauma. An anteroposterior radiograph of the pelvis showed occurrence of a left parasymphyseal fracture (Figure 1E). Non-weight bearing treatment for an additional month followed by gradual resumption of activity was required before clinical and radiological healing occurred.

Case 2

A 64-year-old woman presented with left groin pain without a history of trauma. The

Correspondence: Shigeo Fukunishi, Department of Orthopaedic Surgery Hyogo College of Medicine, Nishinomiya City, Hyogo, Japan
Tel: 81-798-45-6452. Fax: 81-798-45-6453
E-mail: f9457@hyo-med.ac.jp

Key words: rheumatoid arthritis, insufficiency fracture, mutilating change, pelvic fracture, sacral fracture.

Disclosures: the patients and their families were informed that the data from the cases would have been submitted for publication and gave their consent.

Received for publication: 17 July 2009.

Accepted for publication: 9 September 2009.

This work is licensed under a Creative Commons Attribution 3.0 License (by-nc 3.0).

©Copyright S. Fukunishi et al., 2009
Orthopedic Reviews 2009; 1:e23
doi:10.4081/or.2009.e23

pain was mild and she could ambulate. She was diagnosed with RA at the age of 49 years. She had received glucocorticoid (prednisone, 15 mg/day), methotrexate (6 mg/week) and NSAIDs over a period of five years. Her medical history showed she had undergone a right TKA (Figure 2A) and a right wrist arthrodesis (Figure 2B). Radiographs of the hand showed typical mutilating change corresponding to stage V in the Larsen classification of RA (Figure 2B). A radiograph of the pelvis showed a left parasymphyseal fracture (Figure 2C). As a result, we instructed her to reduce her activity level and limit weight bearing by using a walker. Two months after the initial diagnosis, her groin pain was reduced. However, she complained of low back pain thereafter, and her ambulatory ability had become gradually impaired again. A radiograph of the pelvis showed an iliac ala fracture on the same side, while the site of the original parasymphyseal fracture exhibited an appearance of combination of osteolysis and callus formation (Figure 2D). Additional use of a walker for another month was instructed resulting in temporary remission of pain.

Three months later, however, she again complained of right groin pain, without a history of trauma. A repeat radiograph revealed occurrence of a parasymphyseal fracture on the contralateral (right) side. Furthermore, in spite of the continued rest, the follow-up radiograph taken one month later showed an occurrence of a right iliac ala fracture (Figure 2E). Due to persistent pain and weakness caused by prolonged disability, she could not resume ambulating ability and was consequently confined to a wheel chair.

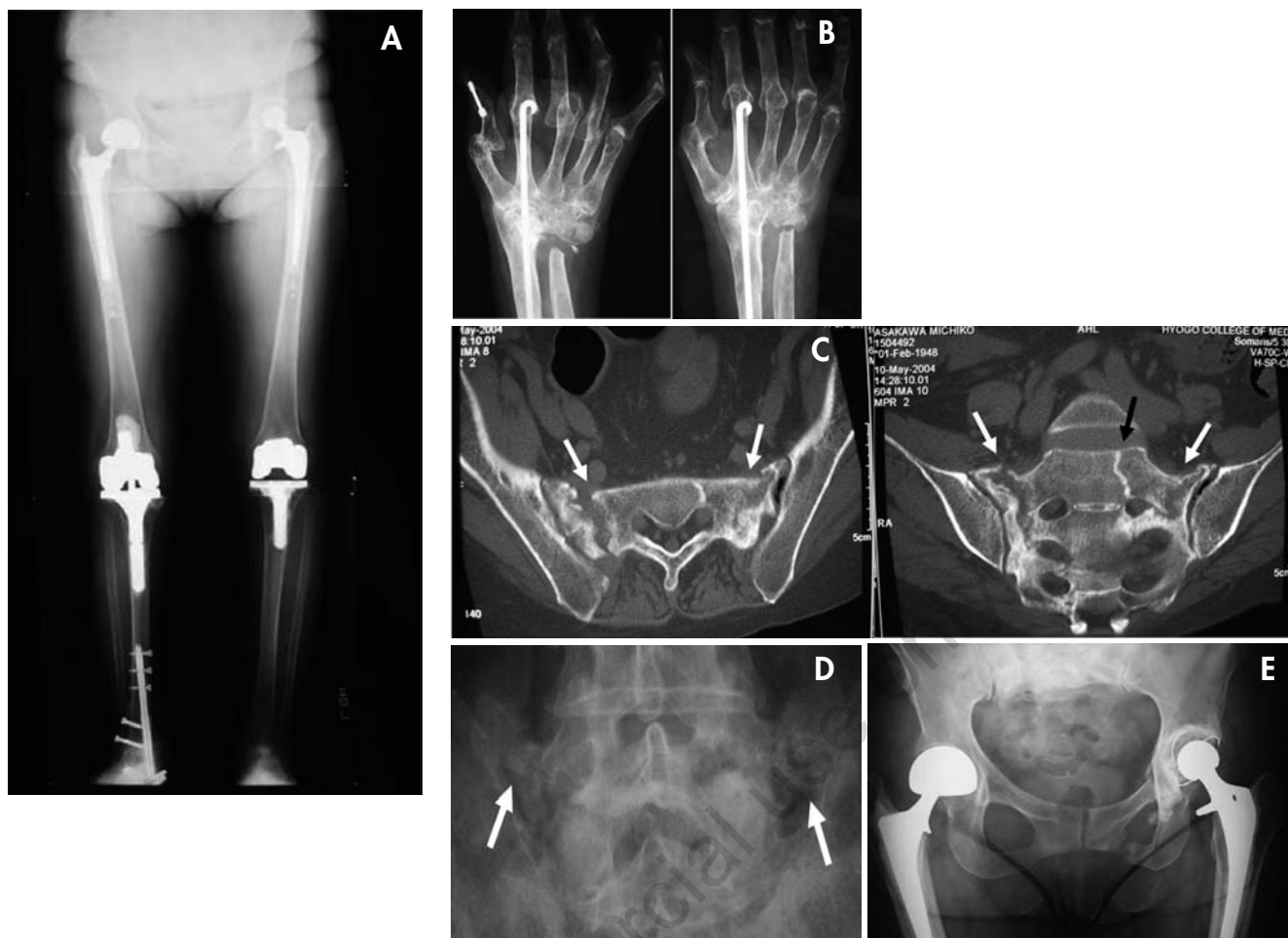


Figure 1. A: Anteroposterior radiographs of both lower extremities showing multiple procedures undergone. The patient underwent a right hip hemiarthroplasty with a bipolar prosthesis, a left total hip arthroplasty, bilateral total knee arthroplasties, a right ankle arthrodesis. B: Anteroposterior radiograph of both hands showing typical mutilating changes. The patient underwent arthrodesis of the bilateral wrists and the metacarpo-phalangeal joint of the right thumb. C: Axial CT images of the sacrum showing linear fracture gaps in the bilateral sacral alae (white arrows) and Denis type II fracture in the right sacrum (black arrow). D: Anteroposterior radiograph of the lumbosacral region showing bilateral fractures of the transverse processes of the fifth vertebra (white arrows). E: Anteroposterior radiograph of the pelvis showing fractures in the left parasymphyseal region and the superior ramus of the left pubis.

Discussion

Insufficiency fractures predominantly occur in postmenopausal women with osteoporosis, and the pelvic ring is most often involved.^{1,9} Other risk factors are chronic systemic diseases such as RA, long-term glucocorticoid use, and the use of radiotherapy.¹² Furthermore, in terms of the stress applied to the bone, increased activity levels after successful lower-extremity surgeries can be an additional risk factor for occurrence of this fracture.³ In the two cases reported in this paper, the patients had combined risk factors, leading to multiple involvements. Mutilating type RA is a subtype of the arthritis characterized by progressive bone and joint destruction with mutilating change. In 1954, Mather first described this disease for patients exhibiting opera glass

hand deformity.¹⁰ Larsen outlined a grading of radiographic changes of the joints in RA patients, and classified the mutilating abnormality as grade V presenting with loss of the original articular structure and severe deformities in weight-bearing joints.¹² Ochi *et al.* investigated the long-term sequence of joint destruction progression in RA patients, and proposed a subset of patients with mutilating disease describing this type as MUD. The pathological features of this disease are characterized by aggravated osteoclastic bone resorption and impaired ligamentous stability.¹¹ These pathologies can predispose the affected patient to fracture even as a result of ordinary stress. Additionally, it is often difficult to control disease activity and patients are usually managed with glucocorticoid with multiple DMARDs. However it has been reported that presence of RA and long-term glucocorti-

coid treatment independently affects the bony quality leading to substantial loss of bony strength.¹³⁻¹⁶

The two patients reported here were diagnosed with mutilating type RA and they also received long-term glucocorticoid treatment with multiple DMARDs. Moreover, both patients underwent successful lower-extremity reconstructive procedures, and increased activity level achieved by those procedures ironically added to the risk factors for occurrence of the insufficiency fractures. Pubic rami insufficiency fractures have been reported as one of the complications after THA. Christiansen reported a series of patients with this complication and attributed the fractures to combined factors of poor bony quality and increased activity level achieved by THA.³ In our clinical experience, 11 patients in 171 RA patients (6.4%) who underwent cemented THA

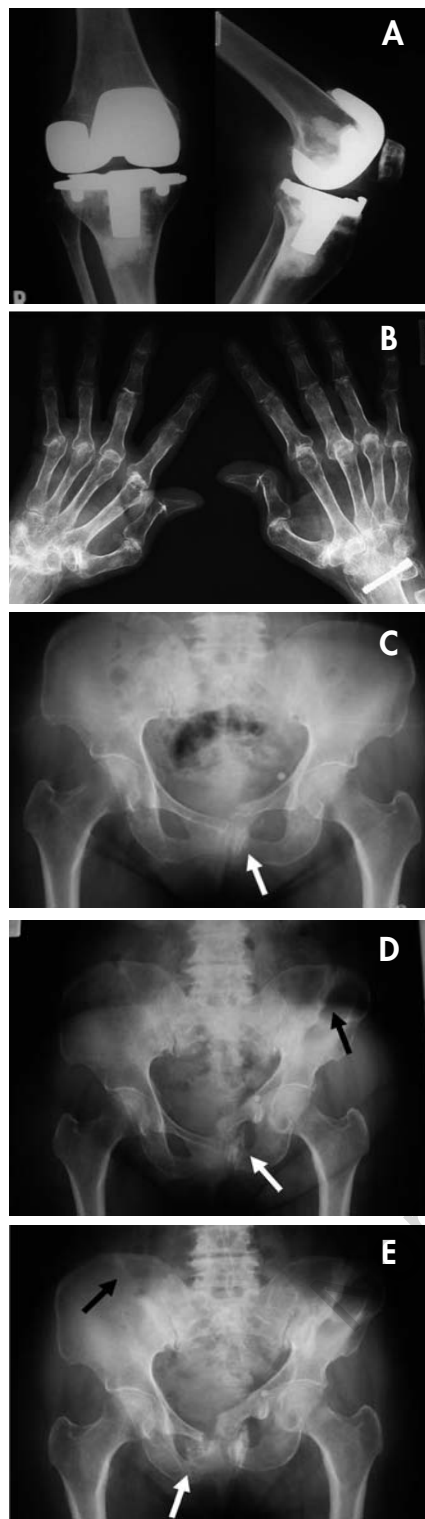


Figure 2. A: anteroposterior and lateral radiographs of the right knee after TKA. B: anteroposterior radiograph of both hands showing typical mutilating changes. The patient underwent Sauve-Kaplanji procedure on the right wrist. C: anteroposterior radiograph of the pelvis showing a left parasymphyseal fracture (white arrow). D: anteroposterior radiograph showing a fracture in the left iliac ala (black arrow). The original parasymphyseal fracture site shows an appearance combining osteolysis and callus formation (white arrow). E: follow-up radiograph taken seven months after the initial fracture. A right iliac ala fracture (black arrow) with a concomitant right parasymphyseal fracture (white arrow) is shown.

arthrodesis before the initial fracture. Especially, both hips, the right knee and the right ankle received surgery within the two years preceding the occurrence of the fracture. The dual-energy X-ray absorptiometry (DEXA) examinations performed before and after the four procedures showed the bone mineral density corresponding to 74% and 61% of the YAM (young adult mean) value respectively. The combined effect of reduced bony strength and increased stress achieved by these surgical procedures could be causative factors for multiple insufficiency fractures in this patient. Prognosis of this fracture is generally good, and fracture healing and improvements in symptoms can be expected within a few months by conservative treatment in the majority of cases.^{1,9} However, in both cases reported here, initial conservative treatment failed, and subsequent additional fractures prolonged the morbidity. Especially, in our case #2 patient, a combination of parasymphyseal and iliac ala fractures resulted in gross instability of the pelvic ring resulting in an inability to walk. The pelvic ring structure and the vertical shear force applied on this area are thought to be responsible for these combined fractures. It has been described that mechanical failure of the posterior arch of the pelvic ring leads to an increase in strain and vertical shear on the anterior arch, and vice versa, resulting in combined anterior and posterior arch fractures with further complicated sequels.¹⁷⁻¹⁹ In the management of patients with multiple risk factors for insufficiency fractures, aggressive interventions including early medication for osteoporosis and careful consultation based on a thorough assessment of the predisposing risk factors for each patient are warranted. Moreover, in the follow-up after lower-extremity reconstructive procedures for these patients, the possibility of an insufficiency fracture should always be considered. When the patient complains of unsp-

suffered from pubic rami fractures postoperatively. With growing awareness of this fracture, aggressive preventive measures for patients with predisposing risk factors have been advocated.^{15,16} In the management guidelines for patients with glucocorticoid-induced osteoporosis, early medication is recommended even for those without apparent reduction in bone mineral density.¹⁶ Our case #1 patient underwent multiple arthroplasties and ankle

fied buttock or groin pain without apparent bony abnormality, next-step examinations such as CT, MRI, and bone scintigraphy should be considered. Early recognition of the fracture followed by proper management may help to improve the prognosis of the patient.

References

1. Soubrier M, Dubost JJ, Boisgard S et al. Insufficiency fracture. A survey of 60 cases and review of the literature. *Joint Bone Spine* 2003; 70:209-18.
2. Nampei A, Hashimoto J, Koyanagi J et al. Characteristics of fracture and related factors in patients with rheumatoid arthritis. *Mod Rheumatol* 2008; 18:170-6.
3. Christiansen CG, Kassim RA, Callaghan JJ, et al. Pubic ramus insufficiency fractures following total hip arthroplasty. A report of six cases. *J Bone Joint Surg Am* 2003; 85:1819-22.
4. Arafat QW, Davies AM. Parasymphyseal insufficiency fracture. *Ann Rheum Dis* 1994; 53:421-4.
5. Dasgupta B, Shah N, Brown H, et al. Sacral insufficiency fracture: an unsuspected cause of low back pain. *Br J Rheumatol* 1998; 37:789-93.
6. Gotis-Graham I, McGuigan L, Diamond T, et al. Sacral insufficiency fractures in the elderly. *J Bone Joint Surg Br* 1994; 76:882-6.
7. Mathers DM, Major GA, Allen L, et al. Insufficiency fracture of the sacrum. *Ann Rheum Dis* 1993; 52:621-3.
8. Schapira D, Militeanu D, Israel O, et al. Insufficiency fractures of the pubic ramus. *Semin Arthritis Rheum* 1996; 25:373-382.
9. West SG, Troutner JL, Baker MR, et al. Sacral insufficiency fractures in rheumatoid arthritis. *Spine* 1994; 19:2117-21.
10. Mather HG. Unusual rheumatoid arthritis (arthritis mutilans). *Proc R Soc Med* 1954; 47:457-9.
11. Ochi T, Iwase R, Yonemasu K, et al. Natural course of joint destruction and fluctuation of serum C1q levels in patients with rheumatoid arthritis. *Arthritis Rheum* 1988; 31:37-43.
12. Larsen A, Dale K, Eek M. Radiographic evaluation of rheumatoid arthritis and related conditions by standard reference films. *Acta Radiol Diagn* 1977; 18:481-91.
13. van Staa TP, Leufkens HG, Cooper C. The epidemiology of corticosteroid-induced osteoporosis: a meta-analysis. *Osteoporosis Int* 2002; 13:777-87.
14. Verstraeten A, Dequeker J. Vertebral and peripheral bone mineral content and fracture incidence in postmenopausal patients with Rheumatoid arthritis: effect of low dose corticosteroids. *Ann Rheum Dis* 1986;

- 45:852-7.
15. NIH Consensus Development Panel on Osteoporosis Prevention, Diagnosis, and Therapy. Osteoporosis prevention, diagnosis, and therapy. JAMA 2001;285:785-95.
 16. Nawata H, Soen S, Takayanagi R et al. Guidelines on the management and treatment of glucocorticoid-induced osteoporosis of the Japanese Society for Bone and Mineral Research (2004). J Bone Miner Metab 2005; 23:105-9.
 17. Aretxabala I, Fraiz E, Pérez-Ruiz F, et al. Sacral insufficiency fractures High association with pubic rami fractures. Clin Rheumatol 2000; 19:399-401.
 18. Davies AM, Evans NS, Struthers GR. Parasympyseal and associated insufficiency fractures of the pelvis and sacrum. Br J Radiol 1988; 61:103-8.
 19. Hoshino Y, Doita M, Yoshikawa M. et al. Unstable pelvic insufficiency fracture in a patient with rheumatoid arthritis. Rheumatol Int 2004; 24:46-9.

Non-commercial use only